

# **Vascular Anomalies in Children**

---

**Shafiqiul Hoque  
Bijoy Krishna Das  
Ruhul Abid**

# **Vascular Anomalies in Children**

## **Professor Shafiqul Hoque**

Chairman, Department of Pediatric Surgery  
Bangabandhu Sheikh Mujib Medical University,  
Dhaka, Bangladesh.

E-mail: [shafiqul@dhaka.net](mailto:shafiqul@dhaka.net)

## **Dr. Bijoy Krishna Das**

Associate Professor and Head  
Department of Pediatric Surgery  
ZH Sikder Women's Medical College  
Dhaka, Bangladesh

E-mail: [drbijoydas1@gmail.com](mailto:drbijoydas1@gmail.com)

## **Dr. Ruhul Abid, MD, PhD**

Assistant Professor of Medicine, Harvard Medical School  
Center for Vascular Biology Research, BIDMC  
Boston, MA 02215, USA

E-mail: [lekhan.abid@gmail.com](mailto:lekhan.abid@gmail.com)

**Published by:**

Hoque, Das & Abid  
Vascular Anomalies Treatment and Research Centre (VATRC)  
CARE Hospital  
2/1, Iqbal Road, Mohammadpur  
Dhaka

**1st Edition**

February 2011

**Copy rights**

Abid, Das & Hoque

**Available at :**

1. Parash Publishers, New Market, Dhaka, Bangladesh
2. Dr. Ruhul Abid, 311 Bedford st. Lexington, Ma 02420, USA  
Tel: 1-781-676-2029

**Printed by:**

Asian Colour Printing  
130 DIT Extension Road  
Fakirerpool, Dhaka-1000  
Phone : 9357726, 8362258

Price : 300 Tk.

US\$ 30.00

## *Dedicated to*

**Our beloved Spouses Nasreen, Lucky & Tahamma Abid  
For their support and sacrifice during the writing of this book.**

## **Preface**

---

This book is motivated by the desire we and others have had to improve our understanding of vascular anomalies or the developmental defects of the blood vessels in children. Any deviation from normal vasculature in the body is known as *vascular anomaly*, involving capillaries, veins, arteries or lymphatic vessels of any organs. We hope that this book will serve a number of goals. The **first goal** is to provide the physicians including pediatricians, surgeons, radiologists, pathologists, and the medical students a solid foundation to understand the pathogenesis, clinical signs and symptoms, diagnostic procedures, treatment and overall management of vascular anomalies. For easy understanding of the medical professionals and interested medical students, we have described each disease under the sub-headings of clinical presentation, diagnosis and management, with a preceding section devoted to shed some lights on our current understanding about the pathogenesis of each disorder. The **second goal** is to educate the concerned parents who would like to know more about the so-called ‘birthmarks’ and ‘hemangiomas’ of their children; they will find this book helpful to understand the disease processes, available treatment options, and prognosis. The **third goal** is to establish a consensus about the importance of the definitive diagnosis for each disease condition *before* initiating any treatment. What is now categorized under the common umbrella of “hemangiomas” is grossly a misnomer. These are, in fact, a diverse arrays of totally different diseases that have only one thing in common that they have arisen from the defects that occurred during the formation of the blood vessels in the fetus. These developmental defects of blood vessels or vascular anomalies usually have two distinct manifestations in the newborn and infants: (1) *tumors of blood vessel* that include hemangioma, hemangioendothelioma and angiosarcoma, and (2) *malformation of blood vessels* that involve capillaries, veins, arteries and lymphatic vessels. **Fourth** is a more pervasive goal to establish an agreement between the clinicians, pathologists and radiologists about the terminology used to describe different vascular anomalies. Since the management of vascular anomalies strictly requires a multidisciplinary approach involving physicians, surgeons, radiologists and pathologists, current lack of an agreement is an obstacle to the advancement of the field. **Finally** and most importantly, this book attests that the first option for the management of most of these anomalies is not surgery or operation, rather it ranges from careful observation and follow-up to pharmacotherapy, sclerotherapy, and surgical intervention/resection.

This book is the results of several years work of the authors in the field at different levels that include clinical practice and research at the molecular level. The current format of this book owes its existence to many of Dr. Abid's discussions with and valuable guidance from Dr. John Mulliken of Vascular Anomalies Center (VAC), Children's Hospital Boston and Harvard Medical School. We are grateful to Dr. Mulliken, who is considered to be the founder of the field, for his edit, valuable scientific and clinical input during the whole process of writing. We are indebted to Drs. Steven Fishman and Ahmad Alomari, Co-Directors of the VAC of Children's Hospital for their unconditional help and continued support.

We would be remiss if we failed to thank Profs. Parveen Fatima and M. Moazzam Hossain of BSMMU and CARE Hospital for their encouragement and support. We would also like to thank Dr. A. Matin, Dr. Imrul Hassan Warsi, and Tanaz Abid for their help with the proofreading process. This list is incomplete and we apologize to anyone we omitted. We also thank our colleagues at the press for their efforts that have been essential in ensuring the successful publication of this high quality book. Finally, we would like to express our sincere thanks to our families for their support and sacrifice during the whole process.

This book is a condensed and authoritative discussion of the management of vascular anomalies based upon the application of fundamental information obtained from clinical and physiological investigations. The mandate for concise presentations in this handbook acknowledges both the time pressures on today's physicians and the desire to make the text affordable and easily understood. Full color figures are placed throughout the text for effective communication. The immense and emerging new information from multiple disciplines makes a synthetic exercise like this book very relevant to help guide medical professionals in the care of their patients.

**Shafiqul Hoque, FCPS, FICS, FACS**

**Bijoy K. Das, MCPS, MS**

**Ruhul Abid, MD, PhD**

## Forward

---

As I began my plastic surgical practice in the 1970s, my chief, Dr. Joseph Murray, suggested I focus on a basic clinical problem, such as “hemangiomas.” In reading the standard texts on this subject, it was painfully obvious that the words used to describe vascular anomalies were unhelpful in caring for my young patients. Every lesion was called “hemangioma.” With the encouragement of Dr. Judah Folkman, Dr. Julie Glowacki and I examined surgical specimens and correlated our findings with clinical behavior. Thus, we wrenched from Mother Nature’s binary classification of vascular anomalies.

At this same period, Mr. Anthony Young from London was a vascular fellow at the Peter Bent Brigham Hospital. We initiated a small “International Workshop for the Study of Vascular Anomalies,” and over the ensuing years, the organization expanded to become the “International Society for the Study of Vascular Anomalies” (ISSVA).

Vascular anomalies insinuate most surgical specialties and many medical specialties as well. The field has grown beyond my imagination. Vascular anomalies centers have formed in many of large academic centers. No longer do these patients wander from physician-to-physician, looking for someone who understands their condition.

I am pleased that such a center has arisen in Dhaka, Bangladesh under the leadership of Dr. Hoque and Dr. Das. This monograph was written by these two pediatric surgeons and their colleague, Dr. Abid, a vascular biologist working at Harvard Medical School. I am privileged to have been of assistance in establishing their unit and reviewing this handbook. I attest that this short text is a distillate of our current knowledge in the emerging field of vascular anomalies. It will serve to educate their colleagues as well as Bangladeshi families. Our team looks forward to helping this first vascular anomalies center in South Asia.

John B. Mulliken, M.D  
Co-Director,  
Vascular Anomalies Center (VAC)  
Children’s Hospital Boston

## Table of Contents

<b>Part – I: Vascular Anomalies – General consideration</b>	<b>08</b>
A. Nomenclature and Historical preview	10
B. Classification	11
C. Pathogenesis of vascular anomalies	13
<b>Part – II: Vascular Anomalies – Clinical Presentation and Management</b>	<b>20</b>
A. Infantile Hemangioma and other vascular tumors	22
B. Vascular malformations	36
a. Capillary Malformations	37
b. Lymphatic Malformations	41
c. Venous Malformations	43
d. Arterial, Arterio-venous Malformations	49
e. Combined Vascular Malformations	52



# **Part – I**

## **Vascular Anomalies – General Consideration**



### **IA. Nomenclature and historical preview:**

Any deviation from normal vasculature in the body is known as *vascular anomaly*, involving capillaries, veins, arteries or lymphatic vessels of any organs. Skin, the largest organ of the body, is usually the most common location of vascular anomalies. The traditional classification/nosology of vascular anomalies, which has its roots in the late 18<sup>th</sup> and early 19<sup>th</sup> century, is very confusing due to its dependence on appearance likened to fruits (e.g. strawberry hemangioma), fish (e.g. salmon patch), or insects (e.g. spider angioma). All congenital vascular anomalies were previously misnamed “hemangioma”, “birthmarks”, and also by non-specific terms such as “neonatal staining”. Another reason for these prevailing misnomers was a clear lack of understanding of the pathogenesis of vascular anomalies. For example, published literature on hemangiomas during the early 19<sup>th</sup> century included “maternal impression” as a mechanism for the development of vascular anomalies. This ‘theory’ stated that the objects or incidence that affected a woman’s mental state during her pregnancy had left an impression on the fetus as a skin blemish<sup>1</sup>. It also suggested that these anomalies resembled the objects or circumstances that influenced the mothers’ emotional state, e.g. strawberry, raspberry or cherries. The traditional nosology still includes these old terms, e.g. strawberry hemangioma, cherry angioma, port-wine stain, salmon patch. The major obstacle has been a lack of agreement between the clinicians, pathologists and radiologists about the terminology used to describe different vascular anomalies.

Rudolf Ludwig Karl Virchow, known as the father of cellular (and surgical) pathology, designated all vascular anomalies as “Angioma” and was the first to categorize them on the basis of their microscopic channel architecture – as angioma simplex, angioma cavernosum and angioma racemosum. Virchow’s assertion prevailed almost throughout the last century with little modifications. Virchow’s angioma simplex became synonymous with “strawberry marks” or “capillary hemangioma”, the latter term was subsequently misapplied to port-wine stain with its capillary sized channels which is now labeled simply as “*hemangioma*”. Similarly angioma cavernosum or cavernous hemangioma were those that never involute<sup>2-4</sup>, which are now labeled as “*venous malformation*”.

The conceptual confusion was further aggravated by the introduction of a new word “hamartoma” to designate developmental anomaly that has the capacity for benign cellular proliferation. *Hamartoma* is a Greek term that implies bodily defect and was first coined by Albrecht in 1904 who defined them as tumor-like malformations in which there was abnormal blending of the normal components of an organ<sup>5</sup>. The term hamartoma is still indiscriminately applied to diverse soft tissue lesions such as neurofibroma, lymphatic malformation, port-wine stain and the common hemangioma of infancy. Usually hamartoma grows at the same rate as the surrounding tissues. Hamartoma is *not* a vascular malformation.

Another important terminologic question in the field is – should the vascular anomalies be called congenital vascular anomaly or developmental vascular anomalies? We favor the simple term *vascular anomalies* as these malformations can be congenital or developmental.

### **IB. Classification:**

There are various types of classification for vascular anomalies. This was, understandably, almost an insurmountable task because of the wide diversity of presentation of vascular lesions. Confusion arose because of an array of admixed histologic and descriptive terms used by different authorities.

In Rome, a consensus on the classification of vascular anomalies was reached by the International Society for the Study of Vascular Anomalies in 1996. This was based on the biological classification originally proposed by Mulliken and Glowacki<sup>6</sup>, and is known as the Expanded ISSVA Classification. In order to increase consensus in the field and to provide guidance for the most appropriate treatment, the ISSVA classification categorizes all vascular anomalies in two major groups: (1) **vascular tumors**, and (2) **vascular malformations**.

In this binary classification, vascular malformations are structural anomalies (e.g. arterial, capillaries, venous malformation, lymphatic malformation) that are distinguishable from the vascular tumors, which are proliferative (e.g. hemangioma, hemangioendothelioma).

**International Society for the Study of Vascular Anomalies (ISSVA) classification :**

**1. Vascular Tumors :**

**a. Hemangioma**

- i. Infantile hemangioma
- ii. Congenital hemangioma:
  - (a) RICH (rapidly involuting congenital hemangioma)
  - (b) NICH (non-involuting congenital hemangioma)

**b. Hemangioendotheliomas**

**c. Angiosarcoma**

**2. Vascular malformations :**

**a. Slow-flow vascular malformations:**

- i. Capillary malformations
  - 1. Port-wine stain
  - 2. Sturge-Weber syndrome
  - 3. Hyperkeratotic vascular stains
  - 4. Cutis marmorata telangiectatica congenita
  - 5. Macrocephaly-cutis marmorata
  - 6. Capillary malformation-arteriovenous malformations
- ii. Telangiectasias
  - 1. Hereditary hemorrhagic telangiectasia (HHT), etc.
- iii. Lymphatic malformations
  - 1. Macrocystic (old term: “Cystic Hygroma”)
  - 2. Microcystic (old term: “Lymphangioma”)
  - 3. Combined
- iv. Venous malformations
  - 1. Sporadic
  - 2. Cerebral-cavernous
  - 3. Glomuvenous (GVM)
  - 4. Cutaneous-mucosal (CMVM)
  - 5. Blue rubber bleb nevus syndrome

**b. Fast-flow vascular malformations:**

- i. Arterial
  - 1. Aneurysm
  - 2. Coarctation
  - 3. Ectasia
  - 4. Stenosis
- ii. Arteriovenous Fistula (AVF)
- iii. Arteriovenous Malformations (AVM)

**c. Combined vascular malformations:**

Slow-flow : Klippel-Trenaunay syndrome (capillaro-lymphatico-venous malformtaion with limb hypertrophy), Proteus syndrome, CLOVES syndrome (congenital lipomatous overgrowth with vascular malformation, epidermal nevi, and skeletal/spinal abnormalities), Maffucci Syndrome .

Fast-flow : Parkes Weber syndrome (multiple subcutaneous, muscular AVFs/AVMs with overgrowth of the affected extremeity)

On the basis of histological and clinical implication, the above classification adopted by ISSVA is practical for the purpose of both diagnosis and treatment.

**IC. Pathogenesis of vascular anomalies:**

The precise mechanism of vascular anomalies (vascular tumors including infantile hemangioma, and vascular malformation), or exactly at what stage of the vascular development the anomalies occur is not known. However, recent findings by several groups have led to a better understanding of the molecular-genetic basis of the pathogenesis of vascular anomalies.

Blood vessel formation in the fetus begins as *vasculogenesis*, which includes differentiation of endothelial cells (ECs) from hemangioblasts and gradual formation of tube-like structures within the pool of ECs. Formation of this tubular network or plexus of ECs is then followed by recruitment of pericytes and smooth muscle cells (SMCs) from the mesenchymal progenitor and neural crest cells<sup>7,8</sup>. ECs play the initiator's role in the formation of blood vessels both in fetal (vasculogenesis) and adult life (angiogenesis). Mesenchymal cells and extracellular matrix also play important roles in this process by regulating differentiation of hemangioblast-derived cells into ECs. In addition, several cytokines and growth factors including vascular endothelial growth factor (VEGF), platelet-derived growth factor (PDGF), transforming growth factor  $\beta$  (TGF $\beta$ ) and angiopoietin have been shown to exert crucial regulatory roles in the formation and maintenance of blood vessels.

Vascular anomalies are usually localized defects of vascular development, often present sporadically in the population with no familial history of lesions. There have always been a number of examples with history of inheritance. These familial forms are often characterized by multifocal small lesions that increase in number with patients' age. Although the inheritance patterns are both autosomal dominant and autosomal recessive, a vast majority of cases demonstrate incomplete penetrance and large clinical variation in inherited vascular anomalies.

The most common vascular anomaly is **infantile hemangioma (IH)**, which is a benign vascular tumor that appears soon after birth<sup>9-11</sup> and usually involutes spontaneously within 6 years of age. A small number of IH can grow very large with destruction of surrounding tissues and organ and may become even life-threatening. Endothelial cells of the hemangioma differ from normal endothelial cells (ECs) in their rates of proliferation and migration. Histologically, during the proliferating phase, infantile hemangioma is highly cellular with clusters of cells expressing endothelial markers including PECAM/CD31, VEGF receptor 1 (VEGFR-1), VEGFR-2, TIE-2 and angiopoietin-2. There are different hypotheses about the pathogenesis of IH, such as local hypoxia (by increasing VEGF production), human papillomavirus-8 infection, and chorionic villus sampling during pregnancy<sup>12, 13</sup>. Recently, the human stem/progenitor cell marker CD133 has been detected in a subset of cells in proliferating IH<sup>14, 15</sup>. These findings suggest involvement of the undifferentiated and/or stem cells in the pathogenesis of these infantile vascular tumors. Isolation of a multipotent progenitor cell from IH capable of de novo blood vessel formation represents a vascular perturbation during a critical period of post-natal growth. Another interesting hypothesis suggested maternal placental endothelial cell as a source of the endothelium lining the vascular channels of IH<sup>16-18</sup>, suggesting that IH arises from displacement of placental cells during fetal development. Recent molecular genetic studies have demonstrated that hemangioma-derived cells originate from the child and not the mother<sup>19</sup>, thus supporting a non-placental source for the ECs of these vascular tumors. There are several recent studies that suggest that somatic mutations in a single Endothelial Progenitor Cell (EPC) results

in clonal expansion of EPC which in turn gives rise to hemangiomas<sup>20</sup>. More recently, molecular-genetic similarities between the hemangioma-derived ECs and the multipotent EPCs have led to another hypothesis that hemangioma may be caused by an aberrant or delayed differentiation of mesodermal progenitor cells into a disorganized mass of blood vessels<sup>20</sup>.

The most common vascular malformation in human is **venous malformations (VM)**. VMs are present usually at birth or may become visible later in life. They can arise in the skin and mucosal vasculatures and affect any organ in the body<sup>4, 21</sup>. VMs present with a variable thickness of the tunica media of the veins resulted from a relative lack of vascular SMCs (VSMCs) and pericytes in the venous walls. The three major types of VM, sporadic (non-inherited) VM, autosomal dominant cutaneomucosal VM (CMVM), and dominantly inherited (familial) glomuvenous VM (GVM) account for 94%, 1%, and 5% of total VMs, respectively. Mutations in the angiopoietin receptor tyrosine kinase TIE2, which plays crucial role in vascular development and angiogenesis, have been shown to be associated with most venous malformations. Somatic hyperactivating mutations in TIE2 are present in 50% of sporadic VM lesions; L914F mutation in TIE2 being present in 85% of the non-inherited sporadic VM lesions<sup>22, 23</sup>. Hyperactivation of TIE2 is believed to cause uncoupling between proliferation of ECs and local recruitment of VSMCs to the endothelial tube-like structures (veins) resulting in VM<sup>24</sup>. In 1996, Vikkula et al. demonstrated that an arginine-to-tryptophan substitution (R849W) in the kinase domain of the angiopoietin receptor TIE2 resulted in the hyperactivity of the receptor tyrosine kinase in two unrelated rare familial CMVMs<sup>24</sup>. Recently, ECs expressing this mutant Tie2 have been shown to recruit and activate Shc, and thus resisting apoptosis (cell death) in the ECs of these vascular lesions<sup>25</sup>. This rare autosomal dominant familial form of venous malformation, mucocutaneous venous malformation (VMCM) or cutaneomucosal VM (CMVM), is characterized by multifocal small bluish cutaneous and mucosal lesions, commonly localized on the tongue and lips. A recent study demonstrated that eight somatic *TIE2* mutations were present in the lesions in 28 out of 57



patients (49.1%) with sporadic VM, however these mutations were not detected in these patients' blood or in control tissues suggesting absence of the same mutations in the germline<sup>22</sup>. These findings suggest that a somatic 2<sup>nd</sup> hit (two-hit hypothesis of Knudson, i.e. 1 hit or mutation in one allele and a 2<sup>nd</sup> hit or mutation in the other allele)<sup>26</sup> was responsible for the development of CMVM by eliminating the protective effects of the wild-type TIE2 allele in these patients. The germline hyperactivation mutation in 60% of CMVM patients was identified as R849W in TIE2 receptor (1<sup>st</sup> hit), and the most frequent somatic mutation in TIE2 was L914F (2<sup>nd</sup> hit)<sup>22</sup>.

The most common familial form of venous malformation is **glomovenous malformation (GVM)**, which mostly affects cutaneous veins, has been shown to be caused by inactivating mutations in a gene named glomulin (*FAP68*). 70% GVMs are inherited in autosomal dominant manner<sup>27, 28</sup>. GVM lesions are small, multifocal or single, hyperkeratotic, and more bluish purple compared to CMVMs. The lesions involve epidermis and subcutaneous layers of the extremities, and usually do not involve mucosa. GVMs are characterized by the presence of smooth-muscle–like glomus cells in the tunica media of the vessels. Glomus cells appear to be incompletely differentiated vascular smooth muscle cells (VSMC) that are positive for SMC markers like  $\alpha$ -actin and vimentin but negative for desmin<sup>29, 30</sup>. 75% of GVM patients have 1 of the 8 common glomulin mutations that seem to alter VSMC phenotype through TGF $\beta$  or hepatocyte growth factor (HGF) signaling pathways<sup>31, 32</sup>. Thus, glomulin is believed to play crucial role in the differentiation of the mesenchymal progenitor cells into VSMCs by modulating these growth factor signaling pathways. One noteworthy observation in all the familial forms of VM is that the inheritance occurs in a paradominant fashion in families, e.g. patients have homozygous loss of function only in the cells of local lesions, whereas the cells of the other organs (i.e. non-affected body parts) of the patients are heterozygous for the mutation and thus remain phenotypically normal.

Flat, reddish lesions, traditionally called **port-wine stains**, are most common **capillary malformation (CM)** (0.3% of live-births), usually affectin head and neck regions, and unlike the common fading birthmarks (salmon patch, angel's kiss), they darken with age. CMs are

usually sporadic and non-familial, however, a new subgroup of CM known as CM-AVM (as part of arteriovenous malformations) has been linked to the mutations in the gene *RASA1* that encodes p120-RasGAP (p120-RasGTPase activating enzyme). These activating mutations in *RASA1* result in increased EC growth, proliferation and altered differentiation<sup>33</sup>.

**Hereditary hemorrhagic telangiectasia (HHT)/Rendu-Osler-Weber syndrome**, is characterized by fragile telangiectatic vessels and arteriovenous malformations. It is an autosomal dominant trait that affects 1 in 8000 people. Cutaneous and mucosal telangiectasias are common presentation along with AVM in the lungs (50% patients), the liver (40%), the gastrointestinal tract (GIT, 25%) and the brain (15%). Epistaxis due to nasal telangiectasias is not uncommon. Common mutations in HHT involve Endoglin (ENG, HHT1) and activin receptor-like kinase (ALK1, HHT2) genes that encode proteins which are important for TGF- $\beta$  signaling in vascular ECs<sup>34, 35</sup>. Recently, mutations in *SMAD4* have also been shown to be associated with HHT<sup>36</sup>. In HHT, there occurs a gradual but sustained alteration in the capillary bed between venules and arterioles resulting in localized dilatation in the capillaries which in turn cause shunting of arteriolar blood directly to the postcapillary venules. In response to the altered flow and pressure, these venules recruit increased number of VSMCs and thus become ‘arterialized’ and convoluted. HHT1 is usually associated with pulmonary AVMs, whereas HHT2 is more commonly associated with hepatic AVMs. Paradoxical inheritance is more common in localized, multifocal lesions wherein the patient inherits a germline mutation from a parent and a 2<sup>nd</sup> hit/mutation affects the other allele of somatic HHT1 or HHT2.

**Cerebral cavernous malformations (CCMs)** involve the vessels of the central nervous system, e.g. the brain, the spinal cord, and the eyes. The lesions are characterized by capillary-like vessels and large sac-like vessels with fibrous walls<sup>37, 38</sup>. 80% of CCMs are sporadic, non-familial, however 20% demonstrate autosomal dominant inheritance trait with the following mutations: CCM1- mutations in *KRIT-1*, CCM2- mutations in malcavernin, and CCM3 – mutations in *PDCD10*<sup>39-41</sup>. Most of the CCM mutations result in the loss of protein function. CCM proteins are believed to act as scaffold proteins. CCM is expressed in

astrocytes, neurons, epithelial, and endothelial cells, whereas CCM2 is expressed in mesenchymal and parenchymal vessels. *KRIT1* interacts with ICAP-1 $\alpha$  ( $\beta$ 1 integrin associated protein 1), which regulates cell migration and adhesion<sup>42</sup>, whereas lack of CCM2 results in hyperactivation of Rho and dilated leaky blood vessels. A recent report proposed that since simvastatin inhibits Rho activity, this cholesterol lowering drug may potentially be used for CCMs<sup>43</sup>. Cutaneous vascular malformations including CMs and VMs are present in 9% of CCM patients (usually with CCM1 and CCM3), and may thus offer as a clue for the diagnosis of the underlying CCMs using appropriate molecular approach; e.g. screening for mutations in the suspected cutaneous lesions. Like GVM and CMVM, CCMs can also be inherited in a paradominant fashion.

**Lymphatic malformations (LMs)** are sporadic lesions without any evidence for familial inheritance suggesting that potential defects or mutations may be somatic events. On the contrary, primary lymphedema, which is characterized by lymphatic accumulation in the tissues due to defect in the lymphatic drainage is usually inherited. Genetic studies of primary lymphedema have revealed molecular signaling pathways in lymphangiogenesis<sup>23, 27</sup>. One variant, *familial congenital lymphedema or Nonne-Milroy syndrome*, is caused by missense mutations in VEGF receptor 3 (VEGFR3/Flt4) and is inherited in an autosomal dominant pattern<sup>44, 45</sup>. 80% of primary lymphedema become evident during puberty and is known as *Meige disease*. One-third of Meige patients have mutations in the *FOXC2* gene, which regulates angiogenesis by modulating the expression of Ang-2, PDGF $\beta$ , and the interaction with VEGF-Notch signaling pathways in ECs<sup>46</sup>. PDGF $\beta$  is overproduced by the lymphatic collecting ducts of Meige patients, which results in increased VSMC recruitment, altered mural tone and dysfunction of the lymphatic vessels<sup>47</sup>. Other forms of primary lymphedema include *hypotrichosis-lymphedema-telangiectasia* (HLT), which is associated with mutations in the *SOX18* gene and characterized by lymphedema, cutaneous telangiectasia and lack of hair<sup>48</sup>. Another rare form is *Hennekam syndrome*, which manifests peripheral and visceral lymphedema, mental retardation and unusual flat face. These patients have mutations in *CCBE1* gene (collagen and calcium-binding EGF domain 1)<sup>49, 50</sup>.

**Ataxia-telangiectasia (AT)** or Louis-Bar Syndrome is a rare autosomal recessive disorder that results from faulty repair of breakages in double-stranded DNA caused by mutations in the *ATM* gene. Clinical presentation of AT is complex and characterized by neurologic abnormalities, immunodeficiency, susceptibility to malignancies, recurrent sinopulmonary infections, and oculocutaneous telangiectasias. Mutation in *ATM* is believed to increase HIF-1 levels, a transcription factor that induces expression of genes involved in growth and proliferation of endothelial cells (e.g., Vascular Endothelial Growth Factor, VEGF) and cellular metabolism (e.g., GLUT-1). Thus, it is plausible that *ATM* deficiency results in aberrant growth of vascular endothelial cells leading to telangiectasia<sup>51, 52</sup>. *Angiokeratoma corporis diffusum universale* or *Fabry disease* is a rare X-linked recessive disorder of sphingolipid metabolism which occurs due to deficiency of the lysosomal enzyme alpha-galactosidase (GLA). Deposits in the lysosomes of endothelial cells (ECs) result in swelling of ECs into the lumen of the blood vessel. Initially, the vessels become narrowed followed by reactive expansion of the blood vessels resulting in cutaneous vascular papules and progressive fatal cardiorenal failure<sup>53</sup>.

It is obvious that many of the vascular anomalies are inherited as an autosomal dominant trait. However, pedigree analysis of these patients can reveal incomplete penetrance resulting in paradominance manifestation. The molecular mechanisms behind this paradominance have been proposed as follows. The germline or inherited mutation (from a parent) in one allele of a given gene may be accompanied by secondary mutations on the other allele of the same gene in the dividing cells during development of the fetus and/or after birth<sup>54</sup>. These somatic mutations, in addition to the original inherited germline mutation, may explain the reasons behind localized lesions and apparently nonhereditary pattern of inherited vascular anomalies. These may also explain why there is large clinical variation in signs and symptoms for the same inherited vascular malformation in the members of a given family or in different families. This requires careful examination of family history and clinical examination of the patients, their parents and siblings. In addition, proper identification of the genetic mutations is also of utmost importance to enable accurate diagnosis, treatment and prognosis.

# **Part – II:**

## **Vascular Anomalies – Clinical Presentation**



The Greek nominative suffix *-oma* means swelling or tumor; however, in modern usage, it denotes a lesion characterized by hyperplasia. This semantic refinement was the key to a binary classification that defines vascular anomalies as *hemangiomas* and vascular *malformations*. The first biological classification based on the cellular features of vascular anomalies correlated the clinical characteristics and natural history was proposed by Mulliken and Glowacki in 1982<sup>1</sup>. In 1996, the Mulliken and Glowacki classification was adopted by the International Society for the Study of Vascular Anomalies (ISSVA) after a minor revision to include all vascular anomalies. This classification is easy to understand and internationally accepted.

*Hemangiomas* are vascular tumors that grow rapidly during the first year of life and usually they *regress* spontaneously over the first one to eight years of life. In contrast, *vascular malformations* are developmental defects resulted from the failure of the proper formation of the vascular tree. Although vascular malformations are present since birth, they enlarge very slowly commensurately with the growth of the child and *never regress*. Histologically, infantile hemangiomas consist of tightly packed sinusoidal channels, lined by abnormal plump hyperproliferative endothelial cells, whereas vascular malformations are composed of abnormal channels with a normal-looking quiescent endothelial lining<sup>21</sup>.

## II A. Hemangioma

Hemangiomas are endothelial vascular tumor with a biological behavior that is unique in the realm of neoplasm, that is they grow rapidly, regress slowly and never recur.

**Infantile Hemangioma:** Infantile hemangioma (IH) is a common vascular tumor that occurs in 3-5% of infants and is usually pinkish or reddish in color, present with a well defined mass, doughy in consistency, and partially or not compressible. Histopathologically, IH is characterized by endothelial cell (EC)-like masses without a defined vascular architecture and disorganized blood vessel-like structures containing red blood cells. Microscopic examination of the hemangioma reveals lobular proliferation of the capillaries surrounded by pericytes and stroma. Endothelial hyperplasia and multilaminated basement membranes in the blood vessels are commonly found in these lesions.

80% infantile hemangiomas (IH) are solitary and 20% are multifocal. There are 3 distinct phases in the life cycle of an IH. These stages are clinically apparent and can be documented by light microscopy and immunohistochemistry. These stages may overlap.

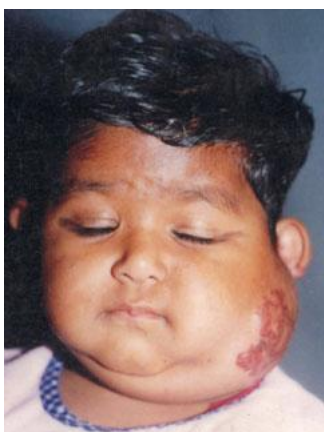**The 3 phases of infantile hemangioma are:**

1. **Proliferating Phase:** (Newborn to 12 months with an average of 8 months.) Rapid growth during first 6 to 12 months of life. As the tumor permeate through superficial dermis, the skin becomes raised, bosselated (small raised projection, protuberant surface), with a vivid crimson color (**Fig. 1a**). If the tumor proliferates deeper into the dermis, the overlying skin may become slightly raised with a bluish hue. Often the tumor is superficial with deeper extension. Histologically, this phase is characterized by endothelial cell masses without a formed vascular structure with occasional disorganized vessel-like structures containing RBCs.

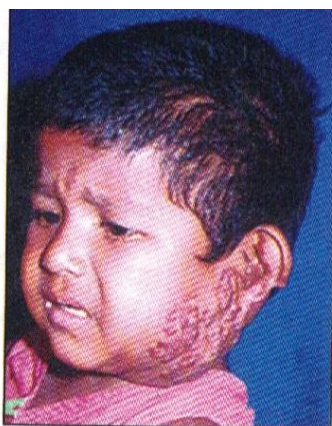**Box -1:** Three phases in the life cycle of infantile hemangioma

1. *Proliferating phase*
2. *Involuting phase*
3. *Involuted Phase*

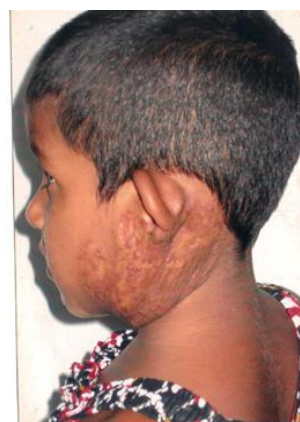2. **Involuting Phase:** ( up to 1-5 years ) Hemangioma reaches its peak by the end of first year of life. The first signs of the involuting phase include alteration in crimson



a. Proliferating phase.



b. Involuting Phase.



c. Involved phase

**Fig 1:** *Hemangioma at Different stages*



color to a dull purplish hue, pale coloration in the surrounding skin with the formation of a patchy grey mantle, and changes in the consistency of the tumor. It feels softer upon touch at this stage (**Fig -1b**). Histologically, the architecture of the blood vessels becomes obvious and enlarged at this stage.

### 3. **Involuted Phase:** ( after age 5 years)

Regression is completed in 50% of children by the age 5 years and in 70% by the age 7 years, with continued improvement until age 10 to 12 years (**Fig. 1c**). Nearly normal skin is restored in 50% cases. Extensive and bulky cutaneous hemangioma can regress totally, conversely whereas a flat, superficial dermal hemangioma can permanently alter skin texture. At this phase of IH, blood vessels are replaced with a fibrofatty tissues and capillary-sized channels.

The rapid growth and subsequent involution of infantile hemangioma is surprisingly different from other vascular tumors. Vascular malformations do not regress and can occur at any time during childhood or adult life<sup>20</sup>.

**Congenital Hemangioma (CH)** is rare. They present as fully grown lesions at birth, and either rapidly regress after birth (usually within first few weeks) or persist. This is a major difference between IH and CH as IH always progress during the neonatal period. Congenital hemangiomas are 2 types – **a.** Rapidly Involuting Congenital Hemangioma (RICH), and **b.** Non-involuting Congenital Hemangioma (NICH)<sup>55-57</sup>.

**(a) RICH:** This tumor presents as a solitary raised, grey or violaceous lesion with ectasia, radial veins, and central telangiectasias with a surrounding pale halo. If the lesion is large enough, there can be sufficient shunting to cause high output congestive cardiac failure. RICH's defining feature is accelerated regression, usually obvious within a few weeks after birth and completed by 6 - 14 months of age.

**(b) NICH:** Well-circumscribed, plaque-like tumor with a pink, blue, or purple rim. NICH grows proportionately with child's growth without regression. There is persistent fast-flow by Doppler or ultrasonic examination. On rare occasions, RICH and NICH may coexist.

### **Cutaneous- Visceral Hemangiomatosis:**

If a child present with multiple cutaneous hemangiomas (more than 5), there is a risk of accompanying visceral hemangioma, particularly in

liver, central nervous system, and gastrointestinal tract. These infants can also present with a triad of congestive heart failure (CHF), hepatomegaly and anemia from birth to 16 weeks of age. Multiple cutaneous hemangiomas are typically small (<3-5 mm in diameter), dark red in color and dome shaped. Visceral hemangiomas are associated with much higher morbidity and mortality rates (40 to 80 percent), because of the lesions with fast-flow, such as those in the liver resulting in high-output cardiac failure<sup>58, 59</sup>. If the liver is diffusely involved, Thyroid Stimulating Hormone (TSH) should be monitored, because severe hypothyroidism may be caused by production of Tri-iodothyronine deiodinase by the tumor<sup>60</sup>.

### **Anatomically Critical or Regionally Important Lesions**

Anatomical location plays a crucial role in determining the seriousness of hemangioma. Small, slowly proliferating lesions may be problematic or even life threatening if they compromise the function of a vital structure. Hemangiomas of the periorbital region pose considerable risk to vision and should be carefully monitored. Amblyopia (visual loss) may result from obstruction of the visual axis. The most common complication, astigmatism, is caused by insidious compression of the cornea, or extension of the tumor into the retrobulbar space. All patients with periocular hemangiomas should be evaluated by an ophthalmologist. Hemangiomas involving the ear may obstruct the external auditory canal, resulting in otitis or a decrease in auditory conduction, which in turn may delay speech development.

### **Histopathology:**

Microscopic examination of the infantile hemangioma reveals lobular proliferation of the capillaries surrounded by pericytes and stroma. Endothelial hyperplasia and multilaminated basement membrane are commonly found in these lesions. Diagnosis of a hemangioma rarely requires histopathologic evaluation unless a definitive diagnosis is not possible from the history, physical examination, and imaging. Histopathology of a proliferating infantile hemangioma usually demonstrates pools of mitotically active, plump ECs that are positive for the glucose transporter GLUT 1<sup>61, 62</sup>.

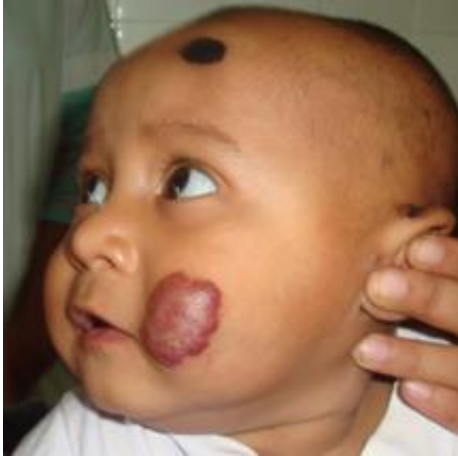### **Clinical Features (Fig. 2; Box -2):**

Infantile hemangioma is the most common tumor of infancy - the frequency in the first few days of life is 1.1 to 2.6% and at the age of 1 year is 10-12% in Caucasian children. Male-to-female ratio is 1:3-5 . It is uncommon in blacks. The hallmark of hemangioma is rapid growth during the neonatal period. They usually appear in the early neonatal period, usually within the first 2 weeks of life as a pink or reddish spot. They may occasionally be seen as nascent lesions at birth, reaching their plateau by the age of 1 year and then regressing by 6 to 10 years of life. Deep subcutaneous tumors or visceral hemangioma(s) may not manifest until 2 to 3 months of life.

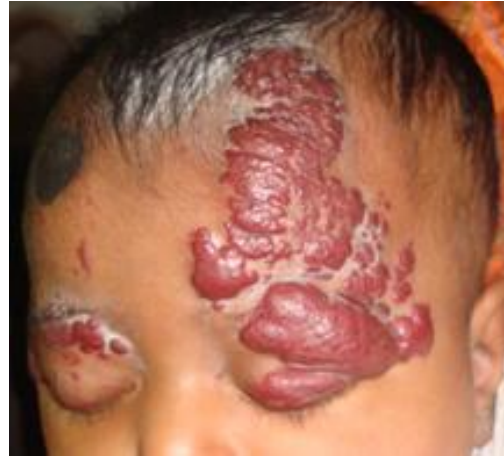### **Box – 2: Clinical Features of Infantile Hemangioma**

*Bosselated (protuberant, raised) crimson colored (deep purplish red) strawberry like mass*  
*Mostly appears within 1<sup>st</sup> two weeks of life as a pink or red color spot*  
*May be nascent at birth*  
*May be multiple*  
*Grows rapidly during neonatal period*  
*Grows less rapidly up to the age of 10-12 months*  
*Regression starts usually after 12 months age and completes by 6-12 years of age*  
*Male & Female ratio is 1: 3-5*  
*Uncommon in Blacks*  
*Skin becomes raised*  
*Non-compressible*  
*May have bluish hue around the mass deep to the skin*  
*80% are single lesion, 20% are multiple lesions*

The skin overlying a deep hemangioma may be only slightly raised with a bluish hue. If the lesion involves both superficial and deep skin layers, the color of skin may become reddish. Dilated local draining veins are often present in these lesions. Deep lesions are occasionally mislabeled as ‘cavernous hemangioma’, and mixed superficial and deep lesions are mislabeled as ‘mixed capillary-cavernous hemangioma’. These adjectives, ‘cavernous’ and ‘mixed capillary cavernous,’ are clinically confusing as they may indicate vascular malformations instead of hemangiomas, and thus should never be used here. Instead, infantile hemangiomas may be categorized as **(i)** superficial, **(ii)** deep, and **(iii)** combined.



*a. Single lesion*



*b. Multiple lesion*

**Fig. 2: Infantile Hemangioma**

**Skeletal Alterations:**

Unlike vascular malformations, infantile hemangiomas do not cause bony distortion or hypertrophy. On the other hand, vascular malformation may cause indentation on the closely associated bone and may cause distortion, hypertrophy, and osteolysis if develops within the bone.

**Associated anomalies may be seen with hemangiomas:**

- PHACES includes
  - P- Dandy-Waker and other cystic malformations in the **P**osterior cranial fossa.
  - H- large often plaque like facial **H**emangioma
  - C- **C**ardiac defects
  - E- **E**ye anomalies
  - S – **S**ternal cleft
- **LUMBAR** anomalies (affect lower half of the body)<sup>63</sup>
  - Lipomeningocele
  - Lower body infantile hemangioma
  - Tethered cord
  - Urogenital anomalies
  - Myelopathy
  - Arterial anomalies
  - Bony deformities
- With perineal and Lower limb hemangioma
  - Urogenital anomaly
  - Anorectal Anomaly

### Complications of Hemangioma:

- Ulceration
- Bleeding
- Destruction, distortion or loss of local tissue structure
- Obstruction of a vital structure
- High output cardiac failure due to diversion of large amount of blood

**Management (Box -3):** Most hemangiomas do not necessitate intervention. Only the deforming, destructive, or obstructing lesions are treated with pharmacotherapy or resection. The clinician should always be careful to include other rare possibilities in the differential diagnosis when the history, clinical examination and imaging are not clear; e.g. a rare, malignant or metastatic tumor may occasionally be mistaken for an infantile hemangioma<sup>64</sup>.

- **Observation**

Small harmless vascular tumors, i.e. infantile hemangioma in a non-vital area can be allowed to proliferate and involute, because they will leave normal or slightly blemished skin. Parents deserve a thorough explanation of the hemangioma's natural history; serial photographs should be used to illustrate this evolution. Scheduled follow-up visits are essential. More frequent visits are necessary whenever a hemangioma is large, ulcerated, multiple, or located in anatomical critical area, e.g. nasal tip hemangioma.

**Local treatment for ulceration and bleeding:**

About 5% of cutaneous hemangioma, more commonly in the lip and anogenital area causes spontaneous epithelial breakdown, ulceration and bleeding. Pressure, topical antibiotic, hydrocolloid dressings are the treatment of choice.

• **Box – 3: Management of Hemangioma**

- *Observation (Expected Treatment)*
- *Local treatment for ulceration and bleeding*
- *Pharmacological therapy:*
  - a. *Corticosteroids*
  - b. *Propranolol*
  - c. *Chemotherapy:*
    1. *Vincristine*
    2. *Cyclophosphamide*
- *Surgical Management*
- *LASER therapy- usually after involution*

- **Pharmacological Therapy:**

Needed for complicated, endangering, life-threatening hemangiomas.

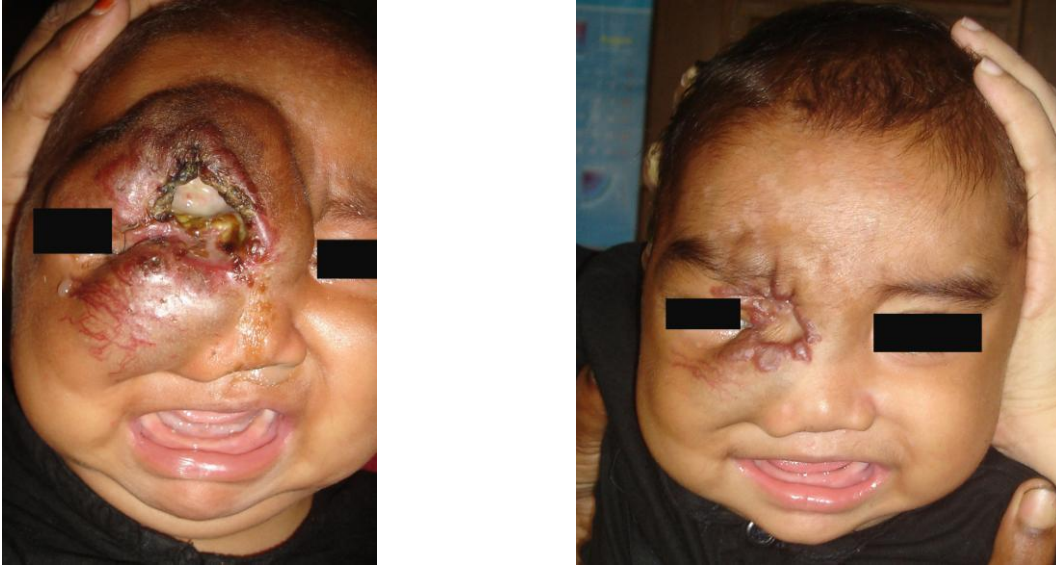- **Corticosteroids:**

**Mode of action of corticosteroids-** Corticosteroids are usually given orally or by injection into the lesions of the complicated and/or life-threatening hemangioma. Corticosteroids are more effective in the early stage of the proliferating phase of infantile hemangioma than in the late stages of the proliferating phase and involuting phase<sup>65</sup>. A recent study demonstrated that corticosteroids, including prednisone, prednisolone and methylprednisolone inhibit expression of VEGF-A, a major vasculo- and angiogenic factor, at the mRNA and protein levels in infantile hemangioma-derived stem cells in *in vitro* tissue culture, and also suppressed vasculogenic potential of hemangioma-derived stem cells in a murine model<sup>66</sup>. Direct inhibition of VEGF-A expression by short hairpin RNA (shRNA) in hemangioma-derived stem cells, but not in hemangioma-derived ECs, resulted in similar suppression of hemangioma. Together, these findings suggest that corticosteroid therapy suppresses infantile hemangioma by inhibiting VEGF-A during the early proliferating phase.

- **Local:** For well localized (<2.5 cm diameter) cutaneous hemangioma.

Triamcinolone (2-3 mg/kg) is injected slowly at a low pressure, ( 3-mL syringe, 30-gauge needle), placing no more than 3 to 5 mg/kg per procedure. Usually 3 to 5 injections are needed, at an interval of 6 to 8 weeks.

- **Systemic:** Oral prednisolone 2-3 mg/kg/day is given as a single morning dose for 4-6 weeks; thereafter the dose is tapered slowly over several months and discontinued by the 10 to 11 months of age. Corticosteroid therapy is often accompanied with H<sub>2</sub> receptor antagonist to reduce gastric irritation caused by the systemic steroids. Side effects of corticosteroids are- diminished growth, cushingoid facies, myopathy, cardiomyopathy, thelarche (breast development), hirsutism, etc. Overall response rate is approximately 85%. In proliferating phase, prednisolone inhibits proliferation and induces regression. *Live vaccines are withheld during steroid therapy.* Diminished growth always returns to normal curves after cessation of steroid therapy.



**Fig. 3 :** Before and after systemic steroid ( Oral Prednisolone)

**Result of oral prednisolone therapy:** A prospective case study of 55 hemangioma patients were carried out. Of 55 cases, 20 were in proliferating phase, 17 were in the early involuting phase and 18 were in the late involuting phase. All the patients were treated with oral prednisolone (3mg/kg/day as a single morning dose). In 2 patients, after initial regression of 2-4 weeks, there was no further regression. All other 53 patients demonstrated excellent response irrespective of the phases of the lesions, patients' age and sex (**Fig. 3**).

- ***Propranolol***

The non-selective  $\beta$ -blocker propranolol is also used to treat complicated infantile hemangioma. The precise mechanism of action of propranolol is not known. Current notion offers vasoconstrictive effects of propranolol on the blood vessels as a mechanism to suppress hemangioma; however, there is no conclusive evidence for this hypothesis. Upon treatment with propranolol, an immediate change in the color of the hemangioma may ensue along with softening of the lesion on palpation. Although there are reports of safe use of propranolol in hemangioma<sup>67-69</sup>, several studies demonstrated risk of serious hypoglycemia, seizures, asthma, and hyperkalemia<sup>70-73</sup>.

Therefore, patients should be closely monitored during propranolol therapy.

There is no uniform / universally recognized clinical protocol. Usually, propranolol is used alone 2-3 mg/kg/day in three divided doses till hemangioma subsides. Use of propranolol in hemangioma needs further research. Propranolol can also be used in conjunction with prednisolone in complicated cases. The combined therapy is usually given as follow: 4 weeks before treatment with propranolol, oral prednisolone 2-3 mg/kg/day for 2 weeks is given followed by 5mg/kg/day for further 2 weeks. Once the steroid is tapered, propranolol can be given 2 mg/kg/day in three divided doses until hemangioma subsides. Propranolol can be stopped without tapering once the hemangioma is involuted.

- ***Interferon  $\alpha$***

Recombinant interferon (IFN) is rarely used now except in older patients. Previously, IFN  $\alpha$ -2a or 2b used to be reserved for the treatment of critical, resistant and life threatening hemangioma. Dosage was 2-3 mU/Sq.m, injected subcutaneously daily for 6-10 months. Patient may develop fever during the first 1-2 weeks. Treatment with acetaminophen 1-2 hours prior to injection dampens the febrile response. *Corticosteroids and IFN should never be co-administered in therapeutic doses.* Corticosteroids should be tapered quickly after IFN administration. IFN is no longer used in infantile hemangioma, however, there are occasional reports of its use in kaposiform hemangioendothelioma (KHE) with Kasabach-Merritt Phenomenon.

**Side effects of IFN:**

1. Spastic diplegia (reversible upon withdrawal of IFN in 50% cases)
2. Reversible toxicoses
3. Transient neutropenia
4. Anemia

- **Chemotherapy:**

Chemotherapeutic agents-

1. Vincristine
2. Cyclophosphamide (rarely given)



**Indications for chemotherapy:**

Failure to respond to corticosteroids or propranolol  
Complications from other therapies

**Side effects of chemotherapy:**

Peripheral neuropathy  
Minor loss of hair (reversible)  
Constipation  
Infection/sepsis  
Anemia

- **Surgical Management:**

(a) **Early resection** prevents complications and disfigurement.

(b) **Aim of resection** of an involuted hemangioma- **Reconstruction** of  
(i) damaged skin, (ii) abnormal contour, (iii) distorted or deformed  
anatomical structure.

(c) **Indication of operation-**

1. Distorted or deformed anatomical structure
2. Rapidly growing large lesions obstructing vital structure/function
3. Reconstruction of disfigured skin after resolution.
4. Freshly appearing lesion in a vital area
5. Frequently bleeding lesion.

If a hemangioma is located in a vital area like lips, nose, eye lids, or near the orifices, early intervention is necessary before it becomes untreatable by pharmacotherapy or resection. If resection does not cause gross disfiguration, it is the 2<sup>nd</sup> best choice of treatment after pharmacotherapy. If there is a risk of disfigurement or functional impairment without surgical intervention, operations are preferred.

- **LASER therapy:**

Tiny telangiectasias and small hemangioma of superficial dermis can be treated effectively by pulsed dye laser (PDL). It is also used to stop bleeding in hemorrhagic hemangiomas and to accelerate healing of ulcerated hemangiomas<sup>74</sup>. PDL is not effective in most other cases including deep or large hemangiomas.

- **Role of Homeopath, Alternative Medicine and Folk (Grameen) Treatment:**

Homeopaths claim that they can treat hemangiomas and vascular malformations. The mechanism of action offered by them as follow: the Homeopathic drug will help the lesion grow rapidly in early phase followed by gradual regression. It is interesting to note here that the natural course of infantile hemangiomas, i.e. the ones that need “observation by a trained physician”, are “Spontaneous Regression” without any intervention. Thus, the ‘credit’ of involution of majority hemangiomas does not go to anyone but the Mother Nature. However, regression process usually begins after the age of one year when some of these lesions may become sufficiently large to cause damage or distortion to surrounding tissues. If these lesions are in anatomically critical region of the body, they may even become life threatening without timely intervention. Thus, leaving a large involuting hemangioma situated in a critical region of the body to Homeopathic or folk medicine, or without any medical intervention may result in severe morbidity or even mortality. In this regard, we should not forget the time-tested phrase- *a stitch in time saves nine*, which may become literally true if we leave even a small lesion without proper observation. Therefore, all the hemangiomas must be seen by a trained medical professional who should decide the **course of treatment**: (a) *observation*, or (b) *intervention* – (i) *pharmacological*, (i) *surgical*, or (iii) *LASER*.

- **Other Vascular Tumors:**

Other vascular tumors (e.g. hemangioendotheliomas, angiosarcoma) are often confused with benign infantile hemangioma or with vascular malformations, however, the etiology, histology, and clinical behavior of these tumors are very different than that of apparently benign IH. If there is any suspicion of malignancy, vascular lesions must be biopsied.

- **Hemangioendothelioma (HE):**

Hemangioendothelioma (HE) is a tumor of the endothelial tissues (endothelium is the innermost single-cell lining of the blood and lymphatic vessels) with low-grade to intermediate malignant potential, i.e. HE ranges between benign hemangiomas and aggressive angiosarcomas. HE can also involve and damage surrounding soft tissues, bone, skin, liver, lymph node and/or lungs.

**There are several types of hemangioendothelioma** depending on their locations and the structures involved, such as *Intravascular Bronchioalveolar Tumor* (Epithelioid Angioendothelioma), *Angioglomoid Tumor* (Epithelioid Angioendothelioma), *Myxoid Angioblastomatosis* (Epithelioid Angioendothelioma), *Dabska's Tumor* (Malignant Endovascular Papillary Angioendothelioma), *Papillary Intralymphatic Angioendothelioma* or PILA (Malignant Endovascular Papillary Angioendothelioma).

Indolent (lazy, inconsistent) slow growing tumor is common in HE. Some cases have been known to go into spontaneous remission, however, some tumors can recur locally and demonstrate invasive properties.

- **Kaposiform hemangioendothelioma (KHE):**

Kaposiform hemangioendothelioma (KHE) is a rare, non-metastasizing but locally aggressive vascular tumor. Previously, KHE was often confused with infantile hemangioma. Unlike infantile hemangioma, KHE rarely regresses spontaneously or completely<sup>75</sup>. Usually, more than 90% KHE present during infancy and early or late childhood, however, there are reports of adult onset<sup>76, 77</sup> and posttraumatic KHE<sup>78</sup>. 50% of all KHE lesions are present at birth<sup>75</sup>. Clinical presentations of KHE include solitary infiltrative ecchymotic induration of the skin and underlying soft tissues along with cutaneous purpura and edema, usually in the trunk, extremities, head and neck<sup>79</sup>. It may also be present retroperitoneally. Coagulopathy and complications from the local invasion of KHE contribute to its high mortality rate of approximately 24%<sup>75</sup>. KHE and tufted angioma, are often associated with thrombocytopenia and coagulopathy (Kasabach-Merritt phenomenon, a platelet-trapping syndrome) and less responsive to pharmacological therapy<sup>80</sup>. Over 50% of KHE patients present with Kasabach-Merritt phenomenon (KMP) as defined by the presence of platelet count less than 25,000/mL and a vascular tumor. The histological features of KHE are characterized by a predominant Kaposi sarcoma-like epithelial cell growth with occasional nodular infiltration

containing poorly canalized vessel-like structures<sup>76</sup>. Characteristic features of KHE include spindle-shaped endothelial cells, diminished pericytes and mast cells, microthrombi, and hemosiderin deposits on light microscopy. Magnetic resonance imaging often demonstrates cutaneous thickening with ill-defined margins, stranding of subcutaneous fat, hemosiderin deposits, and small feeding and draining vessels. Electron microscopy may reveal large gaps between endothelial junctions accompanied with incomplete basement membranes<sup>75</sup>. In patients with hemangioendotheliomas, findings of elevated  $\alpha_1$ -fetoprotein levels may suggest associated hepatoblastoma.

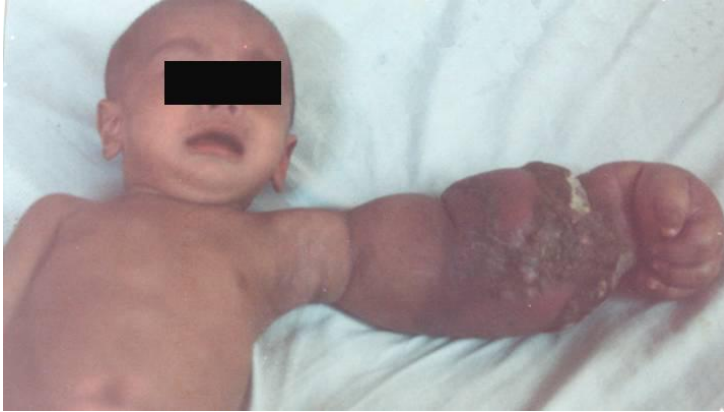### **Kasabach-Merritt Phenomenon:**

A bleeding disorder consisting of hemolytic anemia and severe thrombocytopenia caused by coagulopathy associated with a rapidly growing vascular tumor (**Fig. 3**) is known as Kasabach-Merritt Phenomenon (KMP). It occurs in invasive vascular tumors, particularly in Kaposiform hemangioendothelioma and less frequently in tufted angioma. Thrombocytopenia can be profound ( $<10,000/\text{mL}$ ), however, the prothrombin time (PT) and activated partial thromboplastin time (aPTT) are usually normal or slightly elevated. Hypofibrinogenemia and fibrinolysis are secondary. Patient is at risk for intracranial, pleural-pulmonic, gastrointestinal and intraperitoneal hemorrhage. Biopsy is not indicated. Clinical, hematological, and radiological (MRI) findings of KHE suffice to confirm the diagnosis. One study found that KHE lesion with less than 8 cm in diameter is less likely to cause KMP<sup>81</sup>. In contrast, slow-flow vascular anomalies including venous or large lymphatic malformations may also result in consumptive coagulopathy or disseminated intravascular coagulopathy (DIC)<sup>82</sup>. In case of VM, localized intravascular coagulopathy (LIC) is often associated with elevated D-dimer level, low fibrinogen and normal to mildly decreased platelet count<sup>83</sup>. LIC in VM patients usually correlate with the size of the VM, intramuscular involvement, and presence of phleboliths<sup>84</sup>.

- **Management of KHE:**

Infants who have severe anemia and/or thrombocytopenia can be given blood products. Corticosteroid is the first line of treatment for KHE with KMP. Vincristine and interferon alfa-2a or -2b have also been shown to

be effective in steroid-resistant cases. No single therapy has been shown to result in reproducible shrinkage of the tumor and reversal of KMP<sup>85</sup>. Corticosteroid therapy followed by vincristine has also been reported<sup>76</sup>. Surgical resection is sometimes possible in rare instances where the tumor is very small.



**Fig 4:** *Rapidly growing KHE*

Patient died due to coagulopathy  
(Kasabach-Merritt Phenomenon).

- **Vascular Cancers:**

Vascular cancers (e.g. angiosarcoma) are very rare in children, accounting for only a fraction of 1% of all cancers. Surgical resection, radiotherapy, and chemotherapy have all been used to treat these masses. Although it can occur in all ages, vascular cancer is mostly an adult disease and beyond the scope of this book.

## **II B. Vascular Malformations**

Vascular malformations are almost always present at birth but may not be evident until several weeks after birth. They grow in proportion with body growth. There is no sex or race preponderance or bias. The incidence of venous malformation is about 1.5% in all children. Structural abnormality is often found in the muscular wall (tunica media) of the blood vessels. Spontaneous enlargement or arteriovenous shunting may occur in arteriovenous malformation (AVM) secondary to *trauma, thrombosis, hormonal changes in puberty, during pregnancy, and after anti-ovulation therapy.*

We will describe vascular malformations under *three major sub-categories*: (a) **Slow-flow vascular malformation**, and (b) **Fast-flow vascular malformation**, (c) **Combined Vascular Malformations**.

### **(a) Slow-flow Vascular Malformation:**

#### **(i) Capillary Malformations (CMs)**

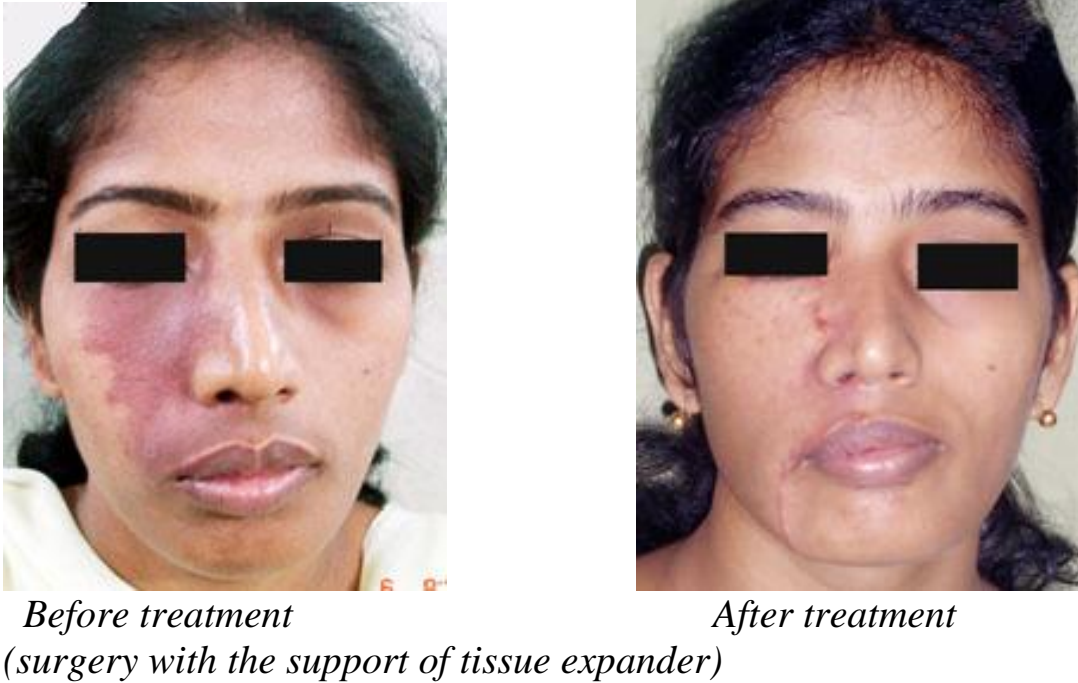##### ***(a) Port-wine stains (Naevus Flammeus):***

Port-wine stains are present at birth and usually persist throughout life. The incidence of port-wine stain is 0.3%<sup>86</sup>. They are macular, red vascular stain that usually involves wide areas (**Fig. 5**). The pink flush, characteristic facial port-wine stains of infancy, gradually darkens to a deep red shade during adulthood, which may become purple later in life. With aging it may become hypertrophic and nodular with a cobblestone surface. Eruptive fibrovascular lesions are frequent complication of CMs in the fifth decade of life. In addition, underlying soft tissue and skeletal hypertrophy may become conspicuous with time. These transformed lesions are resistant to pulsed dye laser (PDL) therapy.

#### **Box 4: Clinical features of Port-wine stains**

- *Macular, red vascular stains, usually in the facial region*
- *Pink flush on facial port-wine stains of infancy*
- *Darker red during adult hood*
- *Purple color during middle age*
- *Hypertrophic, nodular and cobble stone appearance in late life*
- *Soft tissue and skeletal hypertrophy becomes more apparent with age*

Port-wine stains must be differentiated from the common fading macular strains (naevus flammeus neonatorum) that occur in 40% of neonates, which are typically located on the glabella (between the eyebrows), eyelids, nose, upper lip (“angel kiss”), and nuchal area/back of the neck (“stork bite”).



**Fig. 5:** *Capillary Malformations ( Port-wine stain)*

**(b) Sturge-Weber syndrome (SWS):**

Association of facial port-wine staining with glaucoma, ipsilateral leptomeningeal vascular anomalies, and facial overgrowth is known as Sturge-Weber syndrome (SWS)<sup>87</sup>. Clinical presentation includes possible seizures at birth accompanied by capillary malformation (CM) on the forehead, upper eyelid, and soft tissue overgrowth of the lip and boney overgrowth of maxilla. It results from an overabundance of capillaries in the ophthalmic division (V1) of the trigeminal nerve and capillary malformations in the pia arachnoid overlying the brain tissue on the same side of the face as the stain. Leptomeningeal vascular anomaly can result in contralateral convulsions/seizures, glaucoma on the same side as the lesion (50% cases), and variable developmental delay of motor function and cognitive skills. Patients with CM and involvement of maxillary (V2) and mandibular (V3) divisions of the trigeminal dermatome are at low risk for developing this syndrome. It should be noted that many patients with SWS have CMs scattered over trunk and limbs.

History and clinical feature are diagnostic. *MRI of the brain and orbit with contrast are better diagnostic tool for this syndrome than CT.*

Cephalic midline capillary malformations may indicate an associated underlying occipital encephalocele, whereas a dorsal capillary malformation can be suggestive of the presence of cervical or lumbosacral spinal dysraphism (spinal malformation).

**Treatment:** During infancy and early childhood, *Flashlamp pulsed-dye LASER therapy* is the treatment of choice for CMs. For the long-standing port-wine stains which are resistant to laser therapy, surgical resection followed by reconstruction/skin grafting procedures are performed<sup>88</sup>. For SWS, surgical excision and primary closure is useful for small lesions with fibromuscular overgrowth. In older patients with osteogenic overgrowth, skin grafting or rotation flap with or without tissue expander or free flap are performed in SWS.

### (ii) Telangiectasias:

These are tiny anomalies of superficial blood vessels usually involving capillaries, but may also be composed of abnormal aggregation of arterioles or venules. Although they can develop any where in the body, these lesions are more commonly found on the face, upper chest, and neck. Telangiectatic veins found on the legs are called “spider veins”. A bedside test for telangiectasia is blanching by diascopy (application of pressure by a glass slide to see color changes). Female to male ratio is 4:1. Telangiectasias can be congenital or acquired. Precipitating factors for the acquired telangiectasias include age, occupation, and hormonal changes including pregnancy. Telangiectasias may occur in a number of other diseases, e.g. Hereditary Hemorrhagic Telangiectasia (HHT or Rendu-Osler-Weber Syndrome), CREST Syndrome (a variant of scleroderma), Ataxia telangiectasia (AT), Carcinoid Syndrome, Acne Rosacea, etc. The congenital telangiectasias are discussed below.

**Rendu -Osler-Weber Syndrome (hereditary hemorrhagic telangiectasia or HHT ):** This autosomal dominant disease was first distinguished from hemophilia by Rendu in 1896. In 1901, Osler described its clinical manifestation and established it as an inherited disease, which was subsequently confirmed by Weber<sup>89,90</sup>. Histopathology of the disease was first described by Hanes in 1909. He renamed the disease ‘Hereditary Hemorrhagic Telangiectasia’ (HHT)<sup>91</sup>.



HHT is characterized by fragile telangiectatic vessels and arteriovenous malformations (AVM), which affects 1 in 8000 people. Cutaneous and mucosal telangiectasias are common presentation along with AVM in the lungs (50% patients), the liver (40%), the gastrointestinal tract (GIT, 25%) and the brain (15%)<sup>92,93</sup>. Epistaxis due to nasal telangiectasias is the most common presentation due to easy accessibility to minor trauma<sup>92</sup>. GI tract bleeding being the next common presentation followed by hemoptysis<sup>94</sup>.

Discrete spider-like, bright red mucopapules, usually 1 to 4 mm in diameter appear on the skin. They are typically located on the face, lips, tongue, nasal and oral mucous membrane, conjunctiva, palmar aspect of the fingers, and nail beds. Lesions can occur on any mucosal surfaces like vagina, GI tract, and also in lung, liver, spleen, kidney, and brain<sup>92</sup>. The lesions usually arise during early childhood; however, in some cases, they may not become apparent until after puberty. The number of the lesions increases with age. These lesions are prone to ulceration and bleeding, and may thus present with hematemesis, epistaxis, melena, or hematuria. Bleeding in the brain or spinal cord may present with neurological symptoms.

The telangiectatic vessels are dilated and tortuous. Usually small arteries, capillaries, venules, and arteriolar precapillary sphincters that lack elastic fibers are affected. Intact endothelium, continuous basal lamina, inadequate smooth muscle or pericyte on the middle/outer surface of the vessels are characteristic histological features. On ultrastructural studies, conspicuous absence of elastic lamina can be seen in the dilated blood vessels<sup>95</sup>.

### **Treatment of telangiectasia:**

Treatment is complicated. If asymptomatic, telangiectasias can be covered with makeup, otherwise they can be removed by surgery, or treated using sclerotherapy, laser, or PhotoDerm. In case of bleeding from HHT in surgically accessible area, pressure, packing, or microfibrillar collagen can be applied. If needed, skin grafting can also be considered. Telangiectasias can be recurrent. For the treatment of associated pulmonary AVM in HHT patients, therapeutic embolization of arteriovenous pulmonary fistula by catheter technique has been described as the treatment of choice since 1977<sup>93,96</sup>. Successful embolization improves oxygenation by reducing the AVM shunt in the lungs<sup>97-99</sup>.

### (iii) Lymphatic Malformations

The old term “lymphangioma” is a misnomer because the suffix ‘-oma’ implies a potential for growth by cellular mitosis and invasion. These lesions are abnormalities of lymphatic development, yet there is a long standing debate about whether these deformed lymphatics possess proliferative capacity. It is likely that lymphatic malformation expands secondary to fluid accumulation, cellulitis, and/or inadequate drainage of the anomalous lymphatic channels<sup>100</sup>. Anomalous lymphatic channels, vesicles, or pouches filled with lymphs comprise Lymphatic Malformations (LMs). Extravasation of lymph is known as lymphedema, which is also a form of LM. Histologically, LMs are multiple dilated locules of proteinaceous fluid-filled sacs that are lined with single layer of normal looking lymphatic endothelium surrounded connective tissue<sup>6</sup>.

#### **Classification:**

- a) Microcystic (old term: “lymphangioma”)
- b) Macrocystic (old term: “cystic hygroma”)
- c) Combined ( Micro-Macrocystic)

Most LMs are evident at birth or detected before 2 years of age<sup>101</sup>. Although they can suddenly manifest in an older child, they rarely appear in adolescent and adult. Lymphatic malformations *never* regress spontaneously. They usually expand or contract depending on the ebb, direction and amount of flow of the lymphatic fluid, presence of inflammation and/or hemorrhages in the lesions<sup>102, 103</sup>. As with all malformations, the lymphatic endothelial and smooth muscle cells of the LMs are non-proliferative/quiescent. Nodular collection of lymphocytes and few germinal centers containing lymphatic follicles are occasionally found in the surrounding connective tissue of the lymphatic malformation.

#### **Microcystic LMs (old name: “lymphangioma”):**

These microcystic lesions usually present as diffuse swelling with bluish discoloration/hue of skin (**Fig 6a**). These lesions contain small thin-

walled cysts, which may be lobulated or bosselated, soft to rubbery in consistency, not compressible, and usually fixed to skin. They have a honeycombed appearance on cut section. In the head and neck region, the microcystic LMs are usually present above the mylohyoid muscle<sup>104</sup>.

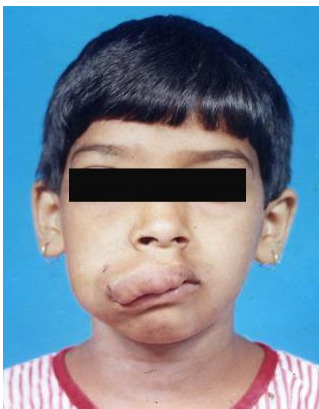**Management of microcystic LMs:** Percutaneous intralesional sclerotherapy is the treatment of choice for microcystic LM; however, surgical resection of the tissue affected may also be required. For mucosal microcystic LMs, the treatment of choice is radiofrequency (RF) ablation, also called coblation; in this procedure, microcystic LMs are destroyed at low temperatures (40°C-70°C) with minimal damage to adjacent tissues<sup>104</sup>.

**Macrocystic LMs (old name: “Cystic Hygroma”):**

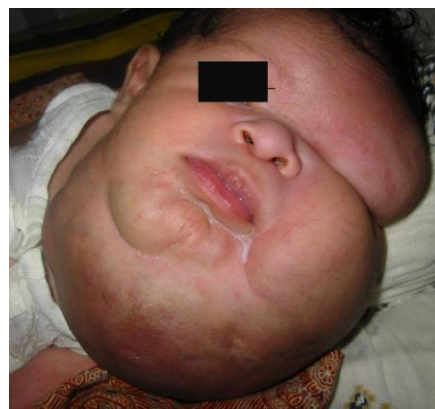Macrocytic LMs are benign, but can be disfiguring and large. These are congenital multiloculated lymphatic lesions that can arise any where in the body, however, they are usually found in the anterior/posterior triangle of the neck, axilla, and groin. Macrocytic LMs can also be associated with posterior nuchal (back of the neck, nape) translucency, fetal hydrops (fluids in fetal compartments), or Turner syndrome (absence of one X chromosome)<sup>105</sup>.

**Differential Diagnosis of macrocystic LMs:** Depends upon sites

(i) Branchial cleft cyst, (ii) Ranula, (iii) Thyroglossal duct cyst



*a. Microcystic*



*b. Macrocystic*

**Fig. 6:** *Lymphatic Malformations*

**Diagnosis:**

Like other vascular malformations, most LMs can be diagnosed clinically<sup>106</sup>. Ultrasonography may be used to confirm the diagnosis. If extension of the lesion into the deeper structure of the body is suspected, CT scan with intravenous contrast enhancement can accurately show the full extension of the lesion. The gold standard is MRI with gadolinium contrast, which is especially helpful for the evaluation of the lesions involving neck, thorax, retro-peritoneum, and the extremities<sup>107-109</sup>. The cysts have low signal intensity on T1-weighted MRI and marked hyperintensity on T2-weighted MRI. Fluid levels within the cysts are common. This is in sharp contrast with the venous malformation, where fluid levels are usually absent but phleboliths (small calculi resulted from venous thrombus) are present.

**Management:** Macrocytic lymphatic malformations can be treated with sclerotherapy. Large cysts are treated with aspiration of lymphatics and instillation of sclerotherapeutic agents (e.g. doxycycline). Several applications may be needed at an interval of 3-4 weeks. Some LMs require surgical removal. Cutaneous LM (*lymphangioma circumscriptum*) requires resection, including the deep fascia, linear closure of the defect, and if necessary, closure with a split thickness skin graft. Sometimes more than one session of resection is required. Osteotomy/ostectomy may be necessary in case of bony involvement.

**Sclerotherapeutic agents:**

- Bleomycin<sup>26e 110</sup>
- OK-432<sup>111</sup>
- Absolute Ethanol<sup>112</sup>
- Doxycycline<sup>113</sup>
- Sodium Tetradecyl Sulfate<sup>114</sup>
- Acetic Acid<sup>115</sup>

**(iv) Venous Malformations (VMs)**

Venous Malformations (**Box – 5**) are soft, spongy, compressible, and non-pulsatile lesions. They feel like a “bag of worms” and expand with gravitational dependency (**Fig. 7**). In cases of craniofacial venous anomaly, Valsalva maneuver or jugular vein compression are used to examine

volumetric expansion. In case of limbs, tourniquets are used for clinical diagnosis. Sometimes VMs may present localized varicosities, ectasias, localized spongy masses, or complex lesions. These lesions can be single or multiple, and may involve any tissues, e.g. skin, muscles, viscera and bones.

**Box – 5: Clinical features of Venous Malformations**

*Ill defined mass*

*Soft, Spongy / Cystic consistency, feels like a bag of worms*

*Usually completely compressible*

*Nodular due to occasional phleboliths*

*Bluish or normal skin color*

*Present at birth, but may not be evident.*

*Commensurate with growth, but may expand rapidly due to intervention*

*Female to male ratio 1:1*

*Normal endothelium, abnormal tunica media*

Phlebothrombosis is a common occurrence in VMs. Recurrent localized pain and tenderness are the frequent presenting complaints. Skin overlying the VM may be normal, however, there may be a bluish hue or dark blue color if the dermis is involved. Combined cutaneous capillary-venous malformations (CVM) have a dark red to purple color. Phleboliths (calculi) can be palpated or seen on radiographic examination, when present. X-rays can also help detect skeletal involvement and overgrowth.

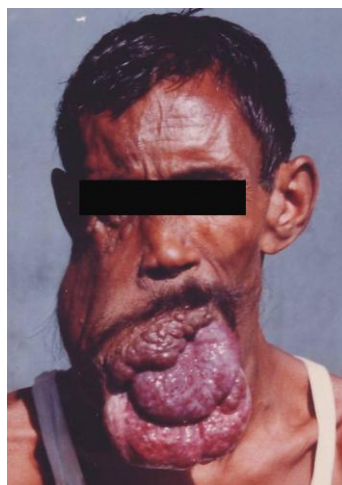
Deep or large VMs with or without phleboliths may present localized intravascular coagulopathy (LIC)<sup>84</sup>, elevated D-dimer levels, and local pain due to thrombosis<sup>116, 117</sup>. Patients with severe DIC may also have low fibrinogen levels (but normal or slightly low platelet count) and a high risk for hemorrhage. Blood stagnation followed by activation of coagulation cascade within the distorted slow-flow channels results in thrombin production, conversion of fibrinogen to fibrin (hence low fibrinogen), and subsequent fibrinolysis. Fibrinolysis gives rise to increased levels of D-dimer, a fibrin degradation product. Palpable phleboliths are usually associated with increased D-dimer levels in VM patients<sup>84</sup>. There are confusions in the literature- LIC in VMs are often incorrectly called ‘Kasabach-Merritt phenomenon’ (KMP), a bleeding disorder predominantly resulted from platelet consumption associated

with kaposiform hemangioendothelioma (vascular tumor). Contrary to KMP, platelets are not involved in LIC or DIC<sup>75, 118</sup>.

Multiple venous malformations may suggest inherited disorders, such as glomuvenous malformation (GVM; defective glomulin), cutaneomucosal VM (CMVM; defective *TIE2*) and cerebral cavernous/capillary malformation (CCM; defective *KRIT1*).

Doppler ultrasonography (DU) is a useful tool to diagnose VMs by differentiating between slow- and fast-flow lesions. MRI can be used to determine the extent of the vascular lesion.

VMs in liver are erroneously called “cavernous hemangiomas”; the term “cavernous” should be only used to describe CCM to reduce confusion in the field. Another rare condition, known as **Blue rubber bleb nevus syndrome (BRBNS)**, consists of multiple VMs involving many organs. The most common sites for this disorder are skin and the GI tract. The lesions are small VMs ranging from 1-3 cm underneath the skin with hard or rubbery consistency. Although the lesions may be present anywhere in the body, they are commonly found on the limbs, trunk, sole of the feet and perineum, and are painful. They blanch upon pressure. Histochemical studies show dysplastic venous channels with flat endothelium and deficient smooth muscle layer<sup>119</sup>. Small intestine is the most common site affected in BRBNS. Barium studies of GI tract is not conclusive for diagnosis of the disorder, however, labeled RBC nuclear scan is helpful in detecting the bleeding site in the GI tract<sup>120</sup>. BRBNS is usually sporadic, but can also be inherited in an autosomal dominant fashion.



**Fig. 7 :** *Venous Malformations (an untreated case)*

The distinguishing features of coagulopathies in Kaposiform Hemangioendothelioma and Venous Malformation are given in Table I<sup>1</sup>.

**Table I: Coagulopathic differences between KMP with KHE and LIC with VMs<sup>121</sup>**

<b>Features</b>	<b>Kaposiform Hemangioendothelioma with KMP</b>	<b>Venous or Lymphaticovenous Malformation with LIC or DIC</b>
<i>Hematologic Findings:</i>		
Platelet	Extremely decreased	Mildly decreased
Fibrinogen	Moderately decreased	Moderately decreased
PT or PTT	Normal or mildly increased	Moderately increased
D-dimer	Mildly increased	Moderately increased
<b>Pathogenesis</b>	Platelet trapping (primary), consumption of fibrinogen (secondary)	Stasis and activation of thrombin on abnormal vasculature
<b>Management</b>	Pharmacologic therapy, avoid platelets, heparin contraindicated	Sclerotherapy, resection, anticoagulation therapy

**Associated Anomalies:** Venous malformations are associated with:

- (i) Maffucci Syndrome
- (ii) Klippel-Trenaunay syndrome
- (iii) Bean Syndrome (Blue rubber bleb nevus syndrome)
- (iv) Turner Syndrome

**Diagnosis:**

In more than 90% of patients, the type of vascular anomaly can be correctly diagnosed by correlating history and findings on clinical examination<sup>106</sup>. Deep subcutaneous, intramuscular, or visceral lesions can be ambiguous, where radiologic evaluation is indicated. Ultrasonography helps to determine whether a vascular malformation is slow-flow or fast-flow, and MRI with contrast agent documents the extent of anatomical involvement of the lesions. Biopsy of a vascular

lesion is *only* necessary when there is a suspicion of malignancy. Venous malformations are usually present as a swelling since birth and grow in proportion with child's age; they never regress.

Patients usually present with visible swelling(s), and overlying normal or bluish hue or dark blue skin. Upon examination, VM feels soft, spongy, usually non-tender, compressible, non-pulsatile, and non transilluminating. VMs are usually ill defined mass. Nodules or bead-like matters may be palpated within the swelling suggesting thrombosis and/or phleboliths.

Elevated D-dimer level indicates sporadic VM. In contrast, VMs with normal level of D-dimer is suggestive of inherited VMs, e.g., CMVM or GVM, or LMs. Low fibrinogen levels suggest ongoing LIC in VM patients, whereas normal platelet count excludes KMP associated with KHE.

**Complications of venous malformation:**

1. Ulceration
2. Bleeding
3. Phleboliths
4. Phlebothrombosis
5. DIC
6. Low grade consumption coagulopathy.
7. Skeletal hypertrophy, distortion or elongation.

**Management:**

Sclerotherapy is the treatment of choice for VMs. If fibrinogen level is normal in VM patients, LIC does not need to be treated. If the lesion is painful, surgical management may be necessary. Elastic compression is effective in minimizing blood stagnation. Special care should be taken during surgical procedures in VM patients with associated LIC; systemic activation of coagulation cascades resulting in DIC (disseminated intravascular coagulopathy) may in turn cause consumption of platelet, fibrinogen and coagulation factors. VM patients with painful lesions due to thrombosis are treated with low molecular weight heparin (LMWH). Response to LMWH is measured



by determining corresponding decrease in D-dimer level and increase in fibrinogen level. In preventing progression of LIC to DIC during an operation, pre- and post-operative use of LMWH has been very effective in patients with an extensive VM<sup>84</sup>.

**Sclerotherapeutic agents:**

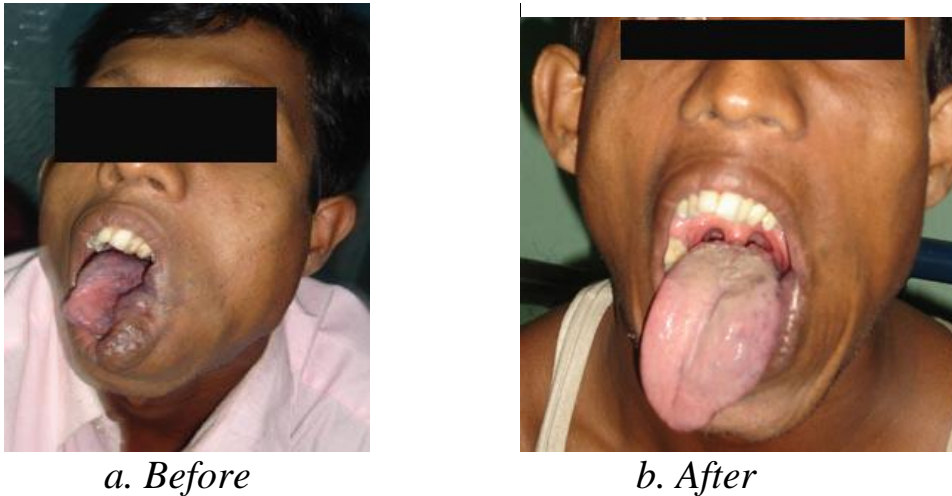1. 5% Ethanolamine Oleate
2. Absolute Ethanol (100% Ethanol)
3. Ethibloc
4. 1% and 3% sodium tetradecyle sulfate
5. Polidocanol

**Other options of management:**

- Combined sclerotherapy and resection – for excision of residual fibrosis, phleboliths, and deformed skin.
- Laser therapy for tiny cutaneous VMs (controversial)

**Results of sclerotherapy treatment on venous malformation with injection Ethanolamine oleate (Fig. 8):** In a prospective case study, 41 patients with venous malformations in the craniofacial area (irrespective of symptoms) were followed clinically for 1 year following treatment. The cases were enrolled between April 2001 and March 2003 in two large referral teaching hospitals in Dhaka, the capital city of Bangladesh. Patients' ages ranged from 3 months to 16 years (mean age 4.3 years). 17 patients were male and 24 were female. The amount of Ethanolamine Oleate per treatment session ranged from 0.50 ml to 5 ml with a maximum dose of 0.40 ml (20 mg) per kg body weight. A 23G/25G butterfly needle was introduced subcutaneously 2-3 mm away from the margin of the lesion before entering the vascular or intravascular compartment. The agent was injected into the vascular compartment. Multiple injections were given to cover the site during each session. For large lesions, injections were repeated at an interval of 3 weeks as a single session could not cover the whole lesion. In one patient, who was having extensive lesions within the oral cavity, oro-pharynx and neck, it took almost 3 years to cover all the lesions by sclerotherapy. At one stage, tracheostomy was needed prior to sclerotherapy on an oro-pharyngeal lesion.

All the treatment sessions were performed as a day surgery/outdoor patient, except in one case where General Anesthesia was employed to treat large lesions within the oral cavity. Patients were evaluated 8 weeks after the last session of sclerotherapeutic injections.



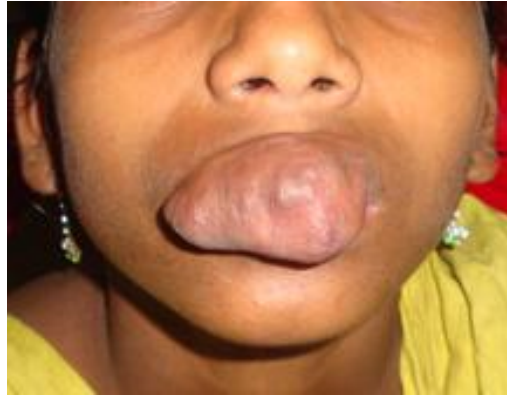**Fig. 8:** *Sclerotherapy with Ethanolamine Oleate of Venous Malformations in the tongue and lower lip.*

42 lesions have undergone 89 sclerotherapy sessions with 19 requiring one, 16 requiring two, and 7 lesions requiring more than two sessions. Sclerotherapy with Ethanolamine Oleate provided complete resolution of symptoms in 41 (97.62%) lesions and significant improvement in 1 lesion. There was no recurrence. All patients experienced pain and swelling to a variable degree for short duration. Skin sloughed out in two patients. No other complications were observed in our study.

### **(b) Fast-flow Vascular Malformations: Arterial, Arteriovenous Malformations**

Arterial Malformations (AMs) are – aneurysm, coarctation, ectasias. They can occur as isolated lesions or in conjunction with arteriovenous malformations (AVMs). *Intracranial AVMs are more common than AVMs in the other parts of the body.* These are present at birth but remain quiescent in infancy and childhood. Puberty and trauma appear to trigger expansion of AVM(**Fig. 9**). Although AVMs are congenital lesions, only 20% of cerebral AVMs are diagnosed during infancy and

early childhood. Cerebrovascular hemorrhage is usually the main clinical presentation in more than 70% pediatric AVM patients resulting in high morbidity and mortality. AVMs within the brain tissue are usually diagnosed in adults<sup>122, 123</sup>.



**Fig. 9:** *Arteriovenous Malformations on the lip [Stage – II]*

Cutaneous AVMs may present as red or violaceous induration with a mass beneath the skin. Usually, local rise of temperature, thrill and bruit are present. Skeletal involvement including maxilla, mandible, and cranium are often recorded; therefore a loose tooth in a bleeding socket of maxilla or mandible should be treated with extreme caution whenever an associated AVM is suspected<sup>124</sup>.

The natural history of AVMs is documented by clinical staging system of Schobinger<sup>124</sup>:

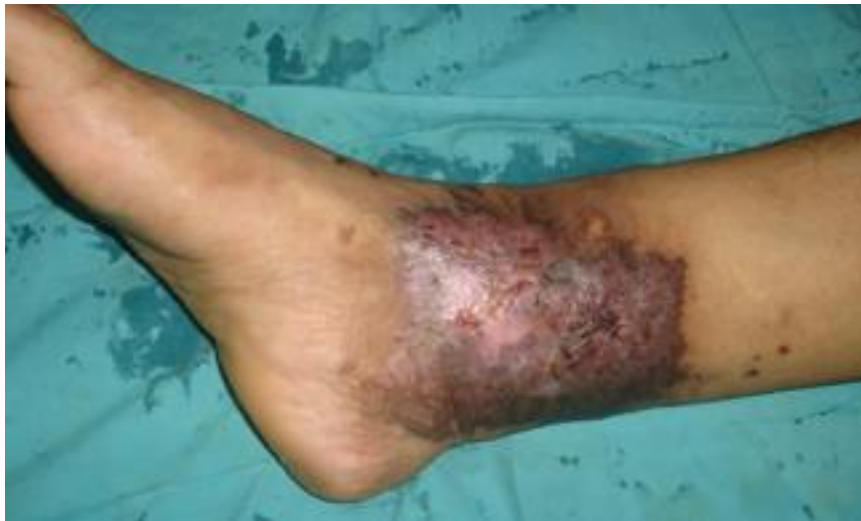**Stage –I (Quiescence)** : Pink-blush stain, warmth, and AV shunting by continuous Doppler or 20-MHz color Doppler.

**Stage – II (Expansion)**: Same as stage I, plus enlargement, pulsations, thrill, bruit, and tortuous/tense veins. **(Fig. 9)**

**Stage – III (Destruction)**: Same as above plus dystrophic changes, ulceration, bleeding, persistent pain, and expansion/destruction. **(Fig. 10)**

**Stage – IV (Decompensation)**: Same as stage – III, plus cardiac failure.

Pulsed Doppler USG and MRI are diagnostic. Super selective angiography is unnecessary until intervention is considered. CT scan and MRI are the best available tools to detect AVMs in brain or other parts of the nervous system. A recently developed MRI-based technique called *magnetic resonance angiography* (MRA) can record both the pattern and velocity of blood flow through vascular lesions and the flow of cerebrospinal fluid (CSF) throughout the brain and spinal cord. MRA provides excellent 3-dimensional representations of the AVMs and their impact on the surrounding neurological tissues.



**Fig. 10:** *Untreated case of AVM with pseudokaposiform changes [Stage – III]*

Untreated cases may become complicated with ulceration and bleeding (**Fig.10**).

### **Management of AVM:**

Cure of AVM is usually not possible; the main aim is to control AVM. Medications are often prescribed to alleviate the symptoms of AVMs including headache, seizures, and pain. Depending on the location and size of the lesions, sclerotherapy, embolization, or resection can be performed. The patient must then be followed up clinically and using ultrasonography and/or MRI for several years. Decision to operate should be carefully considered weighing benefits vs possible risks, and

would require a team consists of neuroradiologist and surgeons familiar with these anomalies. Depending on the size and location of the AVMs, there are 3 major options for the treatment of AVMs:

**(1) Surgical resection/removal:** Extracranial AVM can be ligated or sealed off using laser and then removed using cauterization. For intracranial AVM, “awake brain surgery” (without general anesthesia) is sometimes performed to avoid injury to the brain tissue, e.g. Broca’s speech area.

**(2) Endovascular embolization:** In this process, a catheter is inserted through a leg artery and is placed in the feeding (proximal) artery of the AVM under imaging guidance. An embolizing agent, ethylene-vinyl alcohol copolymer (Onyx), is then injected through the catheter<sup>125-128</sup>. Sometimes proximal reflux of Onyx is prevented by inserting a 4 X 4 mm HyperForm balloon beside the microcatheter. This balloon is then intermittently inflated distal to the Onyx delivery site to prevent proximal reflux<sup>129</sup>. Endovascular embolization (EE) is occasionally performed prior to radiosurgery or resection as EE helps reduce the size of the lesion and makes the AVM amenable to surgical removal<sup>130</sup>. Other embolic agents like n-butyl cyanoacrylate (NBCA) glue, bioactive coils have also been used in EE<sup>131</sup>.

**(3) Stereotactic radiosurgery** (staged or single fraction): This procedure utilizes computer-guided focused radiotherapy to slowly obliterate small AVMs over a period of 1 to 3 years after the exposure. It is non-invasive, usually done in a single session, and does not require general anesthesia. However, it requires a specialized team of neurosurgeon, radiation oncologist and diagnostic radiologist.

### **(c) Combined Vascular Malformations:**

#### **(i) Slow-flow:**

**Klippel-Trenaunay syndrome (KTS):** Klippel-Trenaunay syndrome is a combined vascular malformation characterized by a triad of capillary malformation, varicose veins with or without venous malformations, and lymphatic malformations with bony and soft tissue hypertrophy. KTS is called capillary-lymphaticovenous malformation (CLVM). There is no gender or ethnic predilection. KTS is usually diagnosed by

clinical examination. Work-up of the lesion may involve *noninvasive imaging*: Doppler ultrasound, standard radiography, or magnetic resonance imaging (MRI). Compression garments, sclerotherapy, surgical excision or debulking can be used to contain/control.

**CLOVES syndrome:** CLOVES is abbreviation for congenital lipomatous overgrowth, vascular malformations (CM, LM, VM, AVM), epidermal nevi, and skeletal/scoliosis and spinal abnormalities<sup>132-136</sup>. Acral deformities include wide feet and hands, macrodactyly, and sandal gap<sup>132</sup>. Many patients once called “Proteus” are now categorized as COLVES syndrome that includes CM, LM and VM<sup>136</sup>. The homogeneous features of the lipomatous truncal mass associated with vascular and acral deformities are diagnostic for CLOVES syndrome. MRI may be done to confirm and determine the extent of the involvement of the truncal growth. CLOVES syndrome is a very disabling disorder and thus requires speedy diagnosis and multidisciplinary therapeutic approach. These patients have high risk of pulmonary embolism due to severe, complex vascular anomalies<sup>133</sup>. Association of phlebectasia (dilatation of central or cervical vein) and thromboembolism in these patients should be treated aggressively with anticoagulant therapy including caval filtration (e.g. SVC). Special anticoagulation care should be taken before any surgical procedure in these patients.

**Proteus syndrome:** Proteus Syndrome is a condition that involves atypical growth of the bones, skin, head, with a variety of other symptoms. This condition was first identified by Michael Cohen Jr., DMD, PhD in 1979. In 1983, a German Pediatrician Hans-Rudolf Wiedemann, named it Proteus syndrome, for the Greek God Proteus “the polymorphous”, presumably because of the variable manifestation in the four unrelated boys first identified with the syndrome. At this time there are over 120 documented cases worldwide. Although vascular malformations are listed in the literature, most proven cases of Proteus do not have vascular lesions. Clinical feature of proteus syndrome:  
Partial enlargement of the hands and/or feet, usually asymmetric (Hemihypertrophy)

Pigmented nevi

Tumors – Lipoma, Lymphatic malformation

Cranial anomaly – Macrocephaly

Planter Hyperplasia

**Management** is symptomatic.

**Maffucci Syndrome:** Enchondroma with multiple “angiomas” (Maffucci syndrome) – a genetic disorder, was first reported by Maffucci in 1881. There is no gender bias and lesions are usually asymmetrically distributed. The disease appears to develop in 25% of the cases from the time of birth or during the first year of life, in 45% cases symptoms start before the age of 6, and in 78% cases symptoms develop before puberty<sup>137, 138</sup>. Lewis et al reviewed 98 cases and found that fibula was the most frequently affected bone by enchondromas<sup>138</sup>. The disease appears to develop from mesodermal dysplasia early in life. Patients apparently are of normal intelligence, and no associated mental or psychiatric abnormalities seem to be present.

**Clinical Features:**

- Soft, blue-colored growths on the distal aspects of the extremities.
- Short stature; may have unequal arm or leg lengths due to the bony abnormalities.
- Capillary and venous malformations have been reported in various areas of the body, including the leptomeninges, the eyes, the pharynx, the tongue, the trachea, and the intestines.
- Enchondromas are usually found in the hands (89%), but they can also be found on, although not limited to, the foot, the tibia, the fibula, the femur, the humerus, the ribs, and the skull.
- The tumors (spindle-cell hemangioendothelioma) appear as nodular outgrowths and can cause fracture of the bones, leading to further complications, such as shortened or unequal length of the limbs. Patients who are severely affected can have difficulty walking and manually carrying objects.

**Investigations:**

- Radiologic evaluation of suspicious areas should be conducted. Evidence of malignant transformation includes cortical destruction,
-

endosteal cortical erosion, and zones of lucency within a previously mineralized area.

- CT and/or MRI can help in the evaluation of the lesions and its surrounding soft tissues.
- A biopsy should be performed if there are suspicious radiologic areas. Needle biopsy should provide a diagnosis. Histologically, vascular malformations can be of the capillary (CM) or venous (VM) subtype. Spindle cell hemangioendothelioma commonly occurs in Maffucci syndrome<sup>139, 140</sup>.  
**Treatment** is symptomatic.

**(ii) Fast-flow:**

**Capillary malformation with Arterio-venous malformation (CM-AVM):** Randomly distributed multifocal cutaneous CMs may occasionally be accompanied by AVM. Many of these patients have family histories of vascular anomalies with a mutation in the gene *RASA1* (p120-RasGTPase-activating protein)<sup>141</sup>. *RASA1* is essential for the organization of ECs into highly organized tubular networks. The inheritance pattern of multifocal pink/red/dark CMs with *RASA1* mutation is autosomal dominant. Nearly 50% of CMs present with a pale halo around them and have increased flow (by Doppler) suggestive of possible transformation to AVM. Like other AVMs (e.g. HHT and *PTEN1* hamartoma), these patients are at high risk for intra- and extracranial AVMs. Unlike CM-AVM, CMs of *PTEN1* hamartoma patients are usually deep and intramuscular often associated with lipomatous overgrowth. As mentioned earlier, AVMs in HHT patients are also found in the liver and lungs, whereas CM-AVM affects mostly the face and the limbs. Few patients with *RASA1* mutation also have vein of Galen aneurismal deformities, which is another differentiating feature from other familial AVM cases like HHT and *PTEN1* hamartoma tumor syndrome. Thus, use of cerebral MRI is important for children with multifocal CMs.

**Parkes Weber syndrome (PWS):** PWS is a fast-flow vascular malformation with or without multifocal CMs that are present at birth and worsen with age. Patients with multifocal CMs have germline mutations in *RASA1*. No *RASA1* mutation has been found in PWS with



non-multifocal CM<sup>141</sup>. The patients also have bony and soft tissue hypertrophy with the affected limb being longer than the healthy one. Some patients may show reduced hair density.

In general, patients with *RASA1* mutations are usually at high risk for neurologic tumors.

MRI/MRA is diagnostic.

**Management** is essentially conservative. Staged contour resection or selective amputation may be necessary in some cases.

### Reference:

1. Mulliken JB, Glowacki J. Hemangiomas and vascular malformations in infants and children: a classification based on endothelial characteristics. *Plast Reconstr Surg.* 1982;69:412-422.
2. Fishman SJ. Vascular anomalies of the mediastinum. *Semin Pediatr Surg.* 1999;8:92-98.
3. Low DW. Hemangiomas and vascular malformations. *Semin Pediatr Surg.* 1994;3:40-61.
4. Fishman SJ, Mulliken JB. Hemangiomas and vascular malformations of infancy and childhood. *Pediatr Clin North Am.* 1993;40:1177-1200.
5. Filho OG, Gordan AN, Mello Rde A, Neto CS, Heinke T. Myoid hamartomas of the breast: report of 3 cases and review of the literature. *Int J Surg Pathol.* 2004;12:151-153.
6. Mulliken JB, Glowacki J. Classification of pediatric vascular lesions. *Plast Reconstr Surg.* 1982;70:120-121.
7. Nakamura H. Electron microscopic study of the prenatal development of the thoracic aorta in the rat. *Am J Anat.* 1988;181:406-418.
8. Risau W, Lemmon V. Changes in the vascular extracellular matrix during embryonic vasculogenesis and angiogenesis. *Dev Biol.* 1988;125:441-450.
9. Mulliken JB. Cutaneous vascular anomalies. *Semin Vasc Surg.* 1993;6:204-218.
10. Mulliken JB, Fishman SJ, Burrows PE. Vascular anomalies. *Curr Probl Surg.* 2000;37:517-584.
11. Drolet BA, Esterly NB, Frieden IJ. Hemangiomas in children. *N Engl J Med.* 1999;341:173-181.
12. Holmes LB. Chorionic villus sampling and hemangiomas. *J Craniofac Surg.* 2009;20 Suppl 1:675-677.

13. Kirdar S, Basak S, Odobasi O, Doger FK, Erpek G. Human papillomavirus in rare unilateral benign intranasal tumours. *Rhinology*. 2009;47:349-353.
14. Yu Y, Flint AF, Mulliken JB, Wu JK, Bischoff J. Endothelial progenitor cells in infantile hemangioma. *Blood*. 2004;103:1373-1375.
15. Khan ZA, Melero-Martin JM, Wu X, Paruchuri S, Boscolo E, Mulliken JB, Bischoff J. Endothelial progenitor cells from infantile hemangioma and umbilical cord blood display unique cellular responses to endostatin. *Blood*. 2006;108:915-921.
16. Burton BK, Schulz CJ, Angle B, Burd LI. An increased incidence of haemangiomas in infants born following chorionic villus sampling (CVS). *Prenat Diagn*. 1995;15:209-214.
17. Kaplan P, Normandin J, Jr., Wilson GN, Plauchu H, Lippman A, Vekemans M. Malformations and minor anomalies in children whose mothers had prenatal diagnosis: comparison between CVS and amniocentesis. *Am J Med Genet*. 1990;37:366-370.
18. North PE, Waner M, Mizeracki A, Mrak RE, Nicholas R, Kincannon J, Suen JY, Mihm MC, Jr. A unique microvascular phenotype shared by juvenile hemangiomas and human placenta. *Arch Dermatol*. 2001;137:559-570.
19. Regnier S, Dupin N, Le Danff C, Wassef M, Enjolras O, Aractingi S. Endothelial cells in infantile haemangiomas originate from the child and not from the mother (a fluorescence in situ hybridization-based study). *Br J Dermatol*. 2007;157:158-160.
20. Bischoff J. Progenitor cells in infantile hemangioma. *J Craniofac Surg*. 2009;20 Suppl 1:695-697.
21. Vikkula M, Boon LM, Mulliken JB. Molecular genetics of vascular malformations. *Matrix Biol*. 2001;20:327-335.
22. Limaye N, Wouters V, Uebelhoer M, Tuominen M, Wirkkala R, Mulliken JB, Eklund L, Boon LM, Vikkula M. Somatic mutations in angiopoietin receptor gene TEK cause solitary and multiple sporadic venous malformations. *Nat Genet*. 2009;41:118-124.
23. Limaye N, Boon LM, Vikkula M. From germline towards somatic mutations in the pathophysiology of vascular anomalies. *Hum Mol Genet*. 2009;18:R65-74.
24. Vikkula M, Boon LM, Carraway KL, 3rd, Calvert JT, Diamonti AJ, Goumnerov B, Pasyk KA, Marchuk DA, Warman ML, Cantley LC, Mulliken JB, Olsen BR. Vascular dysmorphogenesis caused by an

- activating mutation in the receptor tyrosine kinase TIE2. *Cell*. 1996;87:1181-1190.
25. Morris PN, Dunmore BJ, Brindle NP. Mutant Tie2 causing venous malformation signals through Shc. *Biochem Biophys Res Commun*. 2006;346:335-338.
  26. Knudson AG, Jr. Mutation and cancer: statistical study of retinoblastoma. *Proc Natl Acad Sci U S A*. 1971;68:820-823.
  27. Brouillard P, Vikkula M. Genetic causes of vascular malformations. *Hum Mol Genet*. 2007;16 Spec No. 2:R140-149.
  28. Boon LM, Mulliken JB, Enjolras O, Vikkula M. Glomuvenous malformation (glomangioma) and venous malformation: distinct clinicopathologic and genetic entities. *Arch Dermatol*. 2004;140:971-976.
  29. McIntyre BA, Brouillard P, Aerts V, Gutierrez-Roelens I, Vikkula M. Glomulin is predominantly expressed in vascular smooth muscle cells in the embryonic and adult mouse. *Gene Expr Patterns*. 2004;4:351-358.
  30. Brouillard P, Ghassibe M, Penington A, Boon LM, Domp Martin A, Temple IK, Cordisco M, Adams D, Piette F, Harper JI, Syed S, Boralevi F, Taieb A, Danda S, Baselga E, Enjolras O, Mulliken JB, Vikkula M. Four common glomulin mutations cause two thirds of glomuvenous malformations ("familial glomangiomas"): evidence for a founder effect. *J Med Genet*. 2005;42:e13.
  31. Chambraud B, Radanyi C, Camonis JH, Shazand K, Rajkowski K, Baulieu EE. FAP48, a new protein that forms specific complexes with both immunophilins FKBP59 and FKBP12. Prevention by the immunosuppressant drugs FK506 and rapamycin. *J Biol Chem*. 1996;271:32923-32929.
  32. Grisendi S, Chambraud B, Gout I, Comoglio PM, Crepaldi T. Ligand-regulated binding of FAP68 to the hepatocyte growth factor receptor. *J Biol Chem*. 2001;276:46632-46638.
  33. Kulkarni SV, Gish G, van der Geer P, Henkemeyer M, Pawson T. Role of p120 Ras-GAP in directed cell movement. *J Cell Biol*. 2000;149:457-470.
  34. Johnson DW, Berg JN, Baldwin MA, Gallione CJ, Marondel I, Yoon SJ, Stenzel TT, Speer M, Pericak-Vance MA, Diamond A, Gutmacher AE, Jackson CE, Attisano L, Kucherlapati R, Porteous ME, Marchuk DA. Mutations in the activin receptor-like kinase 1 gene in hereditary haemorrhagic telangiectasia type 2. *Nat Genet*. 1996;13:189-195.
  35. McAllister KA, Grogg KM, Johnson DW, Gallione CJ, Baldwin MA, Jackson CE, Helmbold EA, Markel DS, McKinnon WC, Murrell J, et al. Endoglin, a TGF-beta binding protein of endothelial cells, is the gene for

- hereditary haemorrhagic telangiectasia type 1. *Nat Genet.* 1994;8:345-351.
36. Gallione CJ, Repetto GM, Legius E, Rustgi AK, Schelley SL, Tejpar S, Mitchell G, Drouin E, Westermann CJ, Marchuk DA. A combined syndrome of juvenile polyposis and hereditary haemorrhagic telangiectasia associated with mutations in MADH4 (SMAD4). *Lancet.* 2004;363:852-859.
  37. Rigamonti D, Hadley MN, Drayer BP, Johnson PC, Hoenig-Rigamonti K, Knight JT, Spetzler RF. Cerebral cavernous malformations. Incidence and familial occurrence. *N Engl J Med.* 1988;319:343-347.
  38. Revencu N, Vikkula M. Cerebral cavernous malformation: new molecular and clinical insights. *J Med Genet.* 2006;43:716-721.
  39. Laberge-le Couteulx S, Jung HH, Labauge P, Houtteville JP, Lescoat C, Cecillon M, Marechal E, Joutel A, Bach JF, Tournier-Lasserre E. Truncating mutations in CCM1, encoding KRIT1, cause hereditary cavernous angiomas. *Nat Genet.* 1999;23:189-193.
  40. Liquori CL, Berg MJ, Siegel AM, Huang E, Zawistowski JS, Stoffer T, Verlaan D, Balogun F, Hughes L, Leedom TP, Plummer NW, Cannella M, Maglione V, Squitieri F, Johnson EW, Rouleau GA, Ptacek L, Marchuk DA. Mutations in a gene encoding a novel protein containing a phosphotyrosine-binding domain cause type 2 cerebral cavernous malformations. *Am J Hum Genet.* 2003;73:1459-1464.
  41. Bergametti F, Denier C, Labauge P, Arnoult M, Boetto S, Clanet M, Coubes P, Echenne B, Ibrahim R, Irthum B, Jacquet G, Lonjon M, Moreau JJ, Neau JP, Parker F, Tremoulet M, Tournier-Lasserre E. Mutations within the programmed cell death 10 gene cause cerebral cavernous malformations. *Am J Hum Genet.* 2005;76:42-51.
  42. Zawistowski JS, Stalheim L, Uhlik MT, Abell AN, Ancrile BB, Johnson GL, Marchuk DA. CCM1 and CCM2 protein interactions in cell signaling: implications for cerebral cavernous malformations pathogenesis. *Hum Mol Genet.* 2005;14:2521-2531.
  43. Whitehead KJ, Chan AC, Navankasattusas S, Koh W, London NR, Ling J, Mayo AH, Drakos SG, Jones CA, Zhu W, Marchuk DA, Davis GE, Li DY. The cerebral cavernous malformation signaling pathway promotes vascular integrity via Rho GTPases. *Nat Med.* 2009;15:177-184.
  44. Lohela M, Bry M, Tammela T, Alitalo K. VEGFs and receptors involved in angiogenesis versus lymphangiogenesis. *Curr Opin Cell Biol.* 2009;21:154-165.

45. Irrthum A, Karkkainen MJ, Devriendt K, Alitalo K, Vikkula M. Congenital hereditary lymphedema caused by a mutation that inactivates VEGFR3 tyrosine kinase. *Am J Hum Genet.* 2000;67:295-301.
46. Hayashi H, Kume T. Foxc transcription factors directly regulate Dll4 and Hey2 expression by interacting with the VEGF-Notch signaling pathways in endothelial cells. *PLoS ONE.* 2008;3:e2401.
47. Petrova TV, Karpanen T, Norrmen C, Mellor R, Tamakoshi T, Finegold D, Ferrell R, Kerjaschki D, Mortimer P, Yla-Herttuala S, Miura N, Alitalo K. Defective valves and abnormal mural cell recruitment underlie lymphatic vascular failure in lymphedema distichiasis. *Nat Med.* 2004;10:974-981.
48. Irrthum A, Devriendt K, Chitayat D, Matthijs G, Glade C, Steijlen PM, Fryns JP, Van Steensel MA, Vikkula M. Mutations in the transcription factor gene SOX18 underlie recessive and dominant forms of hypotrichosis-lymphedema-telangiectasia. *Am J Hum Genet.* 2003;72:1470-1478.
49. Alders M, Hogan BM, Gjini E, Salehi F, Al-Gazali L, Hennekam EA, Holmberg EE, Mannens MM, Mulder MF, Offerhaus GJ, Prescott TE, Schroor EJ, Verheij JB, Witte M, Zwijnenburg PJ, Vikkula M, Schulte-Merker S, Hennekam RC. Mutations in CCBE1 cause generalized lymph vessel dysplasia in humans. *Nat Genet.* 2009;41:1272-1274.
50. Connell F, Kalidas K, Ostergaard P, Brice G, Homfray T, Roberts L, Bunyan DJ, Mitton S, Mansour S, Mortimer P, Jeffery S. Linkage and sequence analysis indicate that CCBE1 is mutated in recessively inherited generalised lymphatic dysplasia. *Hum Genet*;127:231-241.
51. Zhan H, Suzuki T, Aizawa K, Miyagawa K, Nagai R. Ataxia telangiectasia mutated (ATM)-mediated DNA damage response in oxidative stress-induced vascular endothelial cell senescence. *J Biol Chem*;285:29662-29670.
52. Ousset M, Bouquet F, Fallone F, Biard D, Dray C, Valet P, Salles B, Muller C. Loss of ATM positively regulates the expression of hypoxia inducible factor 1 (HIF-1) through oxidative stress: Role in the physiopathology of the disease. *Cell Cycle*;9:2814-2822.
53. Hasholt L, Wandall A, Sorensen SA. Enzyme replacement in Fabry endothelial cells and fibroblasts: uptake experiments and electron microscopical studies. *Clin Genet.* 1988;33:360-371.
54. Boon LM, Ballieux F, Vikkula M. Pathogenesis of vascular anomalies. *Clin Plast Surg*;38:7-19.

55. Berenguer B, Mulliken JB, Enjolras O, Boon LM, Wassef M, Josset P, Burrows PE, Perez-Atayde AR, Kozakewich HP. Rapidly involuting congenital hemangioma: clinical and histopathologic features. *Pediatr Dev Pathol.* 2003;6:495-510.
56. Mulliken JB, Enjolras O. Congenital hemangiomas and infantile hemangioma: missing links. *J Am Acad Dermatol.* 2004;50:875-882.
57. Picard A, Boscolo E, Khan ZA, Barch TC, Mulliken JB, Vazquez MP, Bischoff J. IGF-2 and FLT-1/VEGF-R1 mRNA levels reveal distinctions and similarities between congenital and common infantile hemangioma. *Pediatr Res.* 2008;63:263-267.
58. Boon LM, Burrows PE, Paltiel HJ, Lund DP, Ezekowitz RA, Folkman J, Mulliken JB. Hepatic vascular anomalies in infancy: a twenty-seven-year experience. *J Pediatr.* 1996;129:346-354.
59. Winters RW, Robinson SJ, Bates G. Hemangioma of the liver with heart failure: a case report. *Pediatrics.* 1954;14:117-121.
60. Huang SA, Tu HM, Harney JW, Venihaki M, Butte AJ, Kozakewich HP, Fishman SJ, Larsen PR. Severe hypothyroidism caused by type 3 iodothyronine deiodinase in infantile hemangiomas. *N Engl J Med.* 2000;343:185-189.
61. North PE, Mizeracki A, Mihm MC, Jr., Mrak RE. GLUT1 immunoreaction patterns reliably distinguish hemangioblastoma from metastatic renal cell carcinoma. *Clin Neuropathol.* 2000;19:131-137.
62. North PE, Waner M, Mizeracki A, Mihm MC, Jr. GLUT1: a newly discovered immunohistochemical marker for juvenile hemangiomas. *Hum Pathol.* 2000;31:11-22.
63. Iacobas I, Burrows PE, Frieden IJ, Liang MG, Mulliken JB, Mancini AJ, Kramer D, Paller AS, Silverman R, Wagner AM, Metry DW. LUMBAR: association between cutaneous infantile hemangiomas of the lower body and regional congenital anomalies. *J Pediatr*;157:795-801 e791-797.
64. Hassanein AH, Fishman SJ, Mulliken JB, Alomari AI, Kurek KC, Padua HM, Greene AK. Metastatic neuroblastoma mimicking infantile hemangioma. *J Pediatr Surg*;45:2045-2049.
65. Edgerton MT. The treatment of hemangiomas: with special reference to the role of steroid therapy. *Ann Surg.* 1976;183:517-532.
66. Greenberger S, Boscolo E, Adini I, Mulliken JB, Bischoff J. Corticosteroid suppression of VEGF-A in infantile hemangioma-derived stem cells. *N Engl J Med*;362:1005-1013.

67. Leaute-Labreze C, Dumas de la Roque E, Hubiche T, Boralevi F, Thambo JB, Taieb A. Propranolol for severe hemangiomas of infancy. *N Engl J Med*. 2008;358:2649-2651.
68. Frieden IJ, Drolet BA. Propranolol for infantile hemangiomas: promise, peril, pathogenesis. *Pediatr Dermatol*. 2009;26:642-644.
69. Cheng JF, Gole GA, Sullivan TJ. Propranolol in the management of periorbital infantile haemangioma. *Clin Experiment Ophthalmol*;38:547-553.
70. Fusilli G, Merico G, Gurrado R, Rosa T, Acquafredda A, Cavallo L. Propranolol for infantile haemangiomas and neuroglycopenic seizures. *Acta Paediatr*;99:1756.
71. Bonifazi E, Acquafredda A, Milano A, Montagna O, Laforgia N. Severe hypoglycemia during successful treatment of diffuse hemangiomatosis with propranolol. *Pediatr Dermatol*;27:195-196.
72. Holland KE, Frieden IJ, Frommelt PC, Mancini AJ, Wyatt D, Drolet BA. Hypoglycemia in children taking propranolol for the treatment of infantile hemangioma. *Arch Dermatol*;146:775-778.
73. Pavlakovic H, Kietz S, Lauerer P, Zutt M, Lakomek M. Hyperkalemia complicating propranolol treatment of an infantile hemangioma. *Pediatrics*;126:e1589-1593.
74. Walter JW, Blei F, Anderson JL, Orlow SJ, Speer MC, Marchuk DA. Genetic mapping of a novel familial form of infantile hemangioma. *Am J Med Genet*. 1999;82:77-83.
75. Sarkar M, Mulliken JB, Kozakewich HP, Robertson RL, Burrows PE. Thrombocytopenic coagulopathy (Kasabach-Merritt phenomenon) is associated with Kaposiform hemangioendothelioma and not with common infantile hemangioma. *Plast Reconstr Surg*. 1997;100:1377-1386.
76. Alomari AK, Alomari AI. Picture of the month: kaposiform hemangioendothelioma with Kasabach-Merritt phenomenon. *Arch Pediatr Adolesc Med*;164:387, 388.
77. Zukerberg LR, Nickoloff BJ, Weiss SW. Kaposiform hemangioendothelioma of infancy and childhood. An aggressive neoplasm associated with Kasabach-Merritt syndrome and lymphangiomatosis. *Am J Surg Pathol*. 1993;17:321-328.
78. Karnes JC, Lee BT, Phung T, Alomari AI, Mulliken JB, Greene AK. Adult-onset kaposiform hemangioendothelioma in a posttraumatic site. *Ann Plast Surg*. 2009;62:456-458.
79. Konez O, Burrows PE. Magnetic resonance of vascular anomalies. *Magn Reson Imaging Clin N Am*. 2002;10:363-388, vii.

80. Mueller BU, Mulliken JB. The infant with a vascular tumor. *Semin Perinatol.* 1999;23:332-340.
81. Gruman A, Liang MG, Mulliken JB, Fishman SJ, Burrows PE, Kozakewich HP, Blei F, Frieden IJ. Kaposiform hemangioendothelioma without Kasabach-Merritt phenomenon. *J Am Acad Dermatol.* 2005;52:616-622.
82. Mazereeuw-Hautier J, Syed S, Leisner RI, Harper JJ. Extensive venous/lymphatic malformations causing life-threatening haematological complications. *Br J Dermatol.* 2007;157:558-563.
83. Domp Martin A, Ballieux F, Thibon P, Lequerrec A, Hermans C, Clapuyt P, Barrellier MT, Hammer F, Labbe D, Vikkula M, Boon LM. Elevated D-dimer level in the differential diagnosis of venous malformations. *Arch Dermatol.* 2009;145:1239-1244.
84. Domp Martin A, Acher A, Thibon P, Tourbach S, Hermans C, Deneys V, Pocock B, Lequerrec A, Labbe D, Barrellier MT, Vanwijck R, Vikkula M, Boon LM. Association of localized intravascular coagulopathy with venous malformations. *Arch Dermatol.* 2008;144:873-877.
85. Enjolras O, Mulliken JB, Wassef M, Frieden IJ, Rieu PN, Burrows PE, Salhi A, Leaute-Labreze C, Kozakewich HP. Residual lesions after Kasabach-Merritt phenomenon in 41 patients. *J Am Acad Dermatol.* 2000;42:225-235.
86. Maccollum DW, Martin LW. Hemangiomas in infancy and childhood; a report based on 6479 cases. *Surg Clin North Am.* 1956:1647-1663.
87. Enjolras O, Riche MC, Merland JJ. Facial port-wine stains and Sturge-Weber syndrome. *Pediatrics.* 1985;76:48-51.
88. Tark KC, Lew DH, Lee DW. The fate of long-standing port-wine stain and its surgical management. *Plast Reconstr Surg;*127:784-791.
89. Weber FP. Multiple Hereditary Developmental Angiomata with Recurring Epistaxis. *Proc R Soc Med.* 1908;1:65-66.
90. Weber FP. Multiple Hereditary Developmental Angiomata (Telangiectases), with Recurring Haemorrhages. *Proc R Soc Med.* 1908;1:43-44.
91. Marler JJ, Mulliken JB. Vascular anomalies: classification, diagnosis, and natural history. *Facial Plast Surg Clin North Am.* 2001;9:495-504.
92. Cooke DA. Renal arteriovenous malformation demonstrated angiographically in hereditary haemorrhagic telangiectasia (Rendu-Osler-Weber disease). *J R Soc Med.* 1986;79:744-746.
93. Pollak JS, Saluja S, Thabet A, Henderson KJ, Denbow N, White RI, Jr. Clinical and anatomic outcomes after embolotherapy of pulmonary



- arteriovenous malformations. *J Vasc Interv Radiol*. 2006;17:35-44; quiz 45.
94. Reilly PJ, Nostrant TT. Clinical manifestations of hereditary hemorrhagic telangiectasia. *Am J Gastroenterol*. 1984;79:363-367.
  95. Jahnke V. Ultrastructure of hereditary telangiectasia. *Arch Otolaryngol*. 1970;91:262-265.
  96. White RI, Jr., Lynch-Nyhan A, Terry P, Buescher PC, Farmlett EJ, Charnas L, Shuman K, Kim W, Kinnison M, Mitchell SE. Pulmonary arteriovenous malformations: techniques and long-term outcome of embolotherapy. *Radiology*. 1988;169:663-669.
  97. Haitjema TJ, Overtoom TT, Westermann CJ, Lammers JW. Embolisation of pulmonary arteriovenous malformations: results and follow up in 32 patients. *Thorax*. 1995;50:719-723.
  98. Gupta P, Mordin C, Curtis J, Hughes JM, Shovlin CL, Jackson JE. Pulmonary arteriovenous malformations: effect of embolization on right-to-left shunt, hypoxemia, and exercise tolerance in 66 patients. *AJR Am J Roentgenol*. 2002;179:347-355.
  99. Prasad V, Chan RP, Faughnan ME. Embolotherapy of pulmonary arteriovenous malformations: efficacy of platinum versus stainless steel coils. *J Vasc Interv Radiol*. 2004;15:153-160.
  100. Padwa BL, Hayward PG, Ferraro NF, Mulliken JB. Cervicofacial lymphatic malformation: clinical course, surgical intervention, and pathogenesis of skeletal hypertrophy. *Plast Reconstr Surg*. 1995;95:951-960.
  101. Giguere CM, Bauman NM, Smith RJ. New treatment options for lymphangioma in infants and children. *Ann Otol Rhinol Laryngol*. 2002;111:1066-1075.
  102. Cohen BA. Hemangiomas in infancy and childhood. *Pediatr Ann*. 1987;16:17-26.
  103. Lee BB, Kim YW, Seo JM, Hwang JH, Do YS, Kim DI, Byun HS, Lee SK, Huh SH, Hyun WS. Current concepts in lymphatic malformation. *Vasc Endovascular Surg*. 2005;39:67-81.
  104. Grimmer JF, Mulliken JB, Burrows PE, Rahbar R. Radiofrequency ablation of microcystic lymphatic malformation in the oral cavity. *Arch Otolaryngol Head Neck Surg*. 2006;132:1251-1256.
  105. Alpman A, Cogulu O, Akgul M, Arikan EA, Durmaz B, Karaca E, Sagol S, Ozkinay C, Ozkinay F. Prenatally diagnosed Turner syndrome and cystic hygroma: incidence and reasons for referrals. *Fetal Diagn Ther*. 2009;25:58-61.

106. Finn MC, Glowacki J, Mulliken JB. Congenital vascular lesions: clinical application of a new classification. *J Pediatr Surg.* 1983;18:894-900.
107. Mounayer C, Wassef M, Enjolras O, Boukobza M, Mulliken JB. Facial "glomangiomas": large facial venous malformations with glomus cells. *J Am Acad Dermatol.* 2001;45:239-245.
108. Kern S, Niemeyer C, Darge K, Merz C, Laubenberger J, Uhl M. Differentiation of vascular birthmarks by MR imaging. An investigation of hemangiomas, venous and lymphatic malformations. *Acta Radiol.* 2000;41:453-457.
109. Leung TK, Lee CM, Shen LK, Chen YY. Differential diagnosis of cystic lymphangioma of the pancreas based on imaging features. *J Formos Med Assoc.* 2006;105:512-517.
110. Niramis R, Watanatittan S, Rattanasuwan T. Treatment of cystic hygroma by intralesional bleomycin injection: experience in 70 patients. *Eur J Pediatr Surg;*20:178-182.
111. Okazaki T, Iwatani S, Yanai T, Kobayashi H, Kato Y, Marusasa T, Lane GJ, Yamataka A. Treatment of lymphangioma in children: our experience of 128 cases. *J Pediatr Surg.* 2007;42:386-389.
112. De Santis M, Calo GF, Trombini P, Romagnoli R. Percutaneous sclerosing treatment with ethanol of a large cystic lymphangioma of the neck in an adult. *Radiol Med.* 2003;105:127-130.
113. Mabrut JY, Grandjean JP, Henry L, Chappuis JP, Partensky C, Barth X, Tissot E. [Mesenteric and mesocolic cystic lymphangiomas. Diagnostic and therapeutic management]. *Ann Chir.* 2002;127:343-349.
114. Shiels WE, 2nd, Kang DR, Murakami JW, Hogan MJ, Wiet GJ. Percutaneous treatment of lymphatic malformations. *Otolaryngol Head Neck Surg.* 2009;141:219-224.
115. Park SW, Cha IH, Kim KA, Hong SJ, Park CM, Chung HH. Percutaneous sclerotherapy using acetic acid after failure of alcohol ablation in an intra-abdominal lymphangioma. *Cardiovasc Intervent Radiol.* 2004;27:285-287.
116. Enjolras O, Ciabrini D, Mazoyer E, Laurian C, Herbreteau D. Extensive pure venous malformations in the upper or lower limb: a review of 27 cases. *J Am Acad Dermatol.* 1997;36:219-225.
117. Mazoyer E, Enjolras O, Laurian C, Houdart E, Drouet L. Coagulation abnormalities associated with extensive venous malformations of the limbs: differentiation from Kasabach-Merritt syndrome. *Clin Lab Haematol.* 2002;24:243-251.

118. Hall GW. Kasabach-Merritt syndrome: pathogenesis and management. *Br J Haematol.* 2001;112:851-862.
119. Kassarian A, Fishman SJ, Fox VL, Burrows PE. Imaging characteristics of blue rubber bleb nevus syndrome. *AJR Am J Roentgenol.* 2003;181:1041-1048.
120. Hales K, Connolly LP, Drubach LA, Mulliken JB, Fishman SJ. Tc-99m red blood cell imaging of blue rubber bleb nevus syndrome. *Clin Nucl Med.* 2000;25:835-837.
121. Mulliken JB, Anupindi S, Ezekowitz RA, Mihm MC, Jr. Case records of the Massachusetts General Hospital. Weekly clinicopathological exercises. Case 13-2004. A newborn girl with a large cutaneous lesion, thrombocytopenia, and anemia. *N Engl J Med.* 2004;350:1764-1775.
122. Jomin M, Lesoin F, Lozes G. Prognosis for arteriovenous malformations of the brain in adults based on 150 cases. *Surg Neurol.* 1985;23:362-366.
123. Millar C, Bissonnette B, Humphreys RP. Cerebral arteriovenous malformations in children. *Can J Anaesth.* 1994;41:321-331.
124. Kohout MP, Hansen M, Pribaz JJ, Mulliken JB. Arteriovenous malformations of the head and neck: natural history and management. *Plast Reconstr Surg.* 1998;102:643-654.
125. Arat A, Inci S. Treatment of a superior sagittal sinus dural arteriovenous fistula with Onyx: technical case report. *Neurosurgery.* 2006;59:ONSE169-170; discussion ONSE169-170.
126. Arat A, Cekirge S, Saatci I, Ozgen B. Transvenous injection of Onyx for casting of the cavernous sinus for the treatment of a carotid-cavernous fistula. *Neuroradiology.* 2004;46:1012-1015.
127. Suzuki S, Lee DW, Jahan R, Duckwiler GR, Vinuela F. Transvenous treatment of spontaneous dural carotid-cavernous fistulas using a combination of detachable coils and Onyx. *AJNR Am J Neuroradiol.* 2006;27:1346-1349.
128. Pierot L, Januel AC, Herbreteau D, Barreau X, Drouineau J, Berge J, Sourour N, Cognard C. Endovascular treatment of brain arteriovenous malformations using onyx: preliminary results of a prospective multicenter study. *Interv Neuroradiol.* 2005;11:159-164.
129. Arat A, Cil BE, Vargel I, Turkbey B, Canyigit M, Peynircioglu B, Arat YO. Embolization of high-flow craniofacial vascular malformations with onyx. *AJNR Am J Neuroradiol.* 2007;28:1409-1414.
130. Gailloud P. Endovascular treatment of cerebral arteriovenous malformations. *Tech Vasc Interv Radiol.* 2005;8:118-128.

131. Oka M, Gailloud P. Re: angiographic evidence of aneurysm neck healing following endovascular treatment with bioactive coils. *AJNR Am J Neuroradiol*. 2005;26:2435-2436.
132. Alomari AI. Characterization of a distinct syndrome that associates complex truncal overgrowth, vascular, and acral anomalies: a descriptive study of 18 cases of CLOVES syndrome. *Clin Dysmorphol*. 2009;18:1-7.
133. Alomari AI, Burrows PE, Lee EY, Hedequist DJ, Mulliken JB, Fishman SJ. CLOVES syndrome with thoracic and central phlebectasia: increased risk of pulmonary embolism. *J Thorac Cardiovasc Surg*;140:459-463.
134. Alomari AI, Thiex R, Mulliken JB. Hermann Friedberg's case report: an early description of CLOVES syndrome. *Clin Genet*;78:342-347.
135. Fernandez-Pineda I, Fajardo M, Chaudry G, Alomari AI. Perinatal clinical and imaging features of CLOVES syndrome. *Pediatr Radiol*;40:1436-1439.
136. Sapp JC, Turner JT, van de Kamp JM, van Dijk FS, Lowry RB, Biesecker LG. Newly delineated syndrome of congenital lipomatous overgrowth, vascular malformations, and epidermal nevi (CLOVE syndrome) in seven patients. *Am J Med Genet A*. 2007;143A:2944-2958.
137. Zwenneke Flach H, Ginai AZ, Wolter Oosterhuis J. Best cases from the AFIP. Maffucci syndrome: radiologic and pathologic findings. Armed Forces Institutes of Pathology. *Radiographics*. 2001;21:1311-1316.
138. Lewis RJ, Ketcham AS. Maffucci's syndrome: functional and neoplastic significance. Case report and review of the literature. *J Bone Joint Surg Am*. 1973;55:1465-1479.
139. Fanburg JC, Meis-Kindblom JM, Rosenberg AE. Multiple enchondromas associated with spindle-cell hemangioendotheliomas. An overlooked variant of Maffucci's syndrome. *Am J Surg Pathol*. 1995;19:1029-1038.
140. Perkins P, Weiss SW. Spindle cell hemangioendothelioma. An analysis of 78 cases with reassessment of its pathogenesis and biologic behavior. *Am J Surg Pathol*. 1996;20:1196-1204.
141. Revencu N, Boon LM, Mulliken JB, Enjolras O, Cordisco MR, Burrows PE, Clapuyt P, Hammer F, Dubois J, Baselga E, Brancati F, Carder R, Quintal JM, Dallapiccola B, Fischer G, Frieden IJ, Garzon M, Harper J, Johnson-Patel J, Labreze C, Martorell L, Paltiel HJ, Pohl A, Prendiville J, Quere I, Siegel DH, Valente EM, Van Hagen A, Van Hest L, Vaux KK, Vicente A, Weibel L, Chitayat D, Vikkula M. Parkes Weber syndrome, vein of Galen aneurysmal malformation, and other fast-flow vascular anomalies are caused by RASA1 mutations. *Hum Mutat*. 2008;29:959-65.





**Shafiqul Hoque**

Prof. Shafiqul Hoque, FCPS, FICS, FACS, is the Chairman of the Department of Pediatric Surgery at Bangabandhu Sheikh Mujib Medical University, Dhaka, Bangladesh. He has been honoured with International Guest Scholar of American College of Surgeons, International Federation of Surgical Colleges and Japan Society of Surgeons. He was awarded with "Asir Memorial Gold Medal" for his invention of "Shafiqul's Procedure" for surgical treatment of portal hypertension in children. He has invented surgical retractors/hooks from simple modification of paper clips which was patented in Bangladesh and also honoured with "Rolex Award for enterprise" from Geneva, Switzerland. Dr. Hoque has published many original articles, contributed to book chapters, and served as the Editor-in-Chief of Journal of Bangladesh College of Physicians and Surgeons. He has long-term interests and experience in the management of vascular anomalies and is considered among the pioneers in Bangladesh.



**Bijoy K Das**

Dr. Bijoy Krishna Das MCPS, MS, is an Associate Professor & Head of the Department of Pediatric Surgery & in charge, Department of Plastic Surgery at ZH Sikder Women's Medical College, Dhaka, Bangladesh. He is very much concerned about congenital defects in children. He is a consultant volunteer plastic surgeon of "Operation Smile". He participated in many plastic surgery missions of home and abroad. He is also an active member of many professional organizations in home and abroad like Association of Pediatric Surgeons of Bangladesh, Asian Association of Pediatric Surgeons and many more. Dr. Das has many publications in the national and international journals. His most recent work with Prof. Hoque titled 'Sclerotherapy with ethanolamine oleate for the treatment of Venous malformations' is an excellent contribution to the clinical research of Bangladesh.



**Ruhul Abid**

Dr. Ruhul Abid, MD, PhD is an Assistant Professor of Medicine at Harvard Medical School (HMS) and an internationally acclaimed vascular biologist. In addition to his faculty responsibility at HMS, Dr. Abid is a Principal Investigator at the Center for Vascular Biology Research at Harvard's teaching hospital BIDMC. His major interest is to understand the behavior of vascular endothelium in health and disease. Dr. Abid's work is funded by American Heart Association (AHA) and the National Institutes of Health (NIH), USA. He is the recipient of the AHA's National Young Investigator Award in Thrombosis in 2005, and has recently been awarded the highly prestigious 2011 International Werner Risau Award for Vascular Biology. He works in close collaboration with Drs. Mulliken, Fishman and Alomari at the Vascular Anomalies Center at Children's Hospital, Boston.